

قسم علوم الحياة / كلية العلوم – جامعة بغداد

علم الديدان الطفيلية -مرحلة رابعة-

صباحي + مسائي

Helminthology

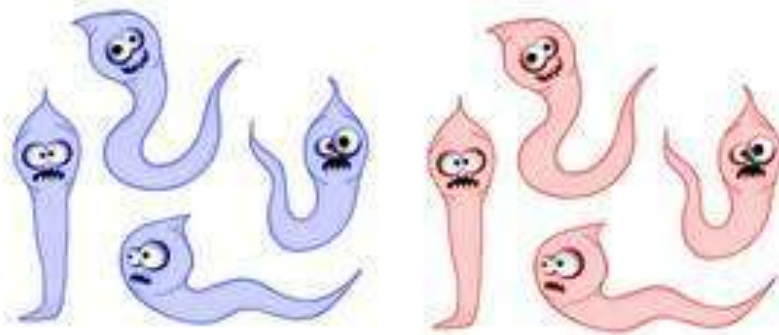
4th grade

أ.م.د. انتصار جبار صاحب

م.د. رشا حسين كبة

أ.م.د. حيدر زهير علي

م.د. امجد قيس ابراهيم



Medical Helminthology علم الديدان الطبية

Introduction:

The field of medicine that relates to helminths (worms) which are capable of causing infectious disease to humans and/or animals.

Helminthes are trophoblastic metazoa (multicellular) eukaryotic animals spend part or entire life cycle in a human or host. They generally possess digestive, circulatory, nervous, excretory, and reproductive systems. Some are free-living in soil and water, while the helminthes of medical importance are parasitize on human or animal. Helminthes parasites are more complex than free-living helminthes, because they have evolved mechanisms to deal with the different environments of their various hosts and living conditions.

Helminthes cause different diseases in humans worldwide, on a global basis it is estimated that up to 500 million people may be infected at any given time with pinworms. Although few helminthic infections cause life- threatening diseases. They cause anemia and malnutrition, in children they cause a reduction in academic performance. Helminthes also cause economic loss, as a result of infections of domestic animals. There is age dependent distribution of infections from geo-helminthes and schistosomes.

The sources of the parasites are different. Exposure of humans to the worms may occur in one of the following ways:

- 1- Contaminated soil (Geo-helminthes), water (cercariae of blood flukes) and food (*Taenia* in raw meat).
- 2- Blood sucking insects or arthropods as in filarial worms.
- 3- Domestic or wild animals harboring the parasite as in *Echinococcus* in cats.
- 4- Person to person as in *Enterobius vermicularis*, *Hymenolopis nana*.
- 5- Oneself (autoinfection) as in *Enterobius vermicularis*.

Helminthes are studied in microbiology because they cause infectious diseases and most are diagnosed by microscopic examination of eggs or larvae (main infective stages of worms).

Worms do harm their hosts in the following ways:

- 1- By causing irritation, as in *Fasciola*.
- 2- By absorbing the food intended for the host, as in tapeworms.
- 3- By sucking blood or lymph, as in hookworms.
- 4- By feeding on the tissues of the host, as in *Ascaris*.
- 5- By causing mechanical obstruction and pressure, as in microfilaria.
- 6- By causing the growth of nodules and tumors and by perforating vessels, as in *Opisthorchis felinus* and *Wuchereria bancrofti*.
- 7- By causing wounds through the site of infection, as in *Ascaris* or by reducing the resistance of the host to other infections, as in lungworm.
- 8- By secreting toxins or harmful substances, e.g. anti-coagulants secreted by hookworms, anti-digestive enzymes secreted by intestinal worms.
- 9- By transmitting casual agents of infectious disease, such as bacteria, viruses, blood protozoa and spirochaetes.

Signs and symptoms of worm's infection:

Helminthes inhabit most areas of the world and produce a large proportion of the parasitic infections suffered by humans. Signs and symptoms are many and varied and are dependent upon the type of worm with which the victim is infected. People with intestinal worms infections are usually undernourished and weak, and may be concurrently infected with viruses, fungi, or bacteria. The malnourished state may also lead to certain types of chemical and metal poisoning due to toxins excreted by the parasites. There is no difference in age or gender of those who experience parasitism, as human intestinal parasites can be present with any disease, in any person, and at any age.

Certain intestinal worms called flukes may cause severe disease of the gastrointestinal tract, bladder, or liver and may destroy large numbers of blood cells. Some parasitic worms have the ability to fool bodies into thinking they are normal part of the tissue or organ and the immune system will not fight off the intruders. They can break down, damage, or block organs of the body by forming clumps as balls or tumors, and sometimes are even mistaken for cancer tumors. A number of species are also able to travel to the brain, heart, and lungs, where they invade the tissues of these vital organs. An important clinical finding is seen in the CBC (complete Blood Count) of infected person do worms cause an increase number of eosinophils (eosinophilia) as response to allergic reaction.

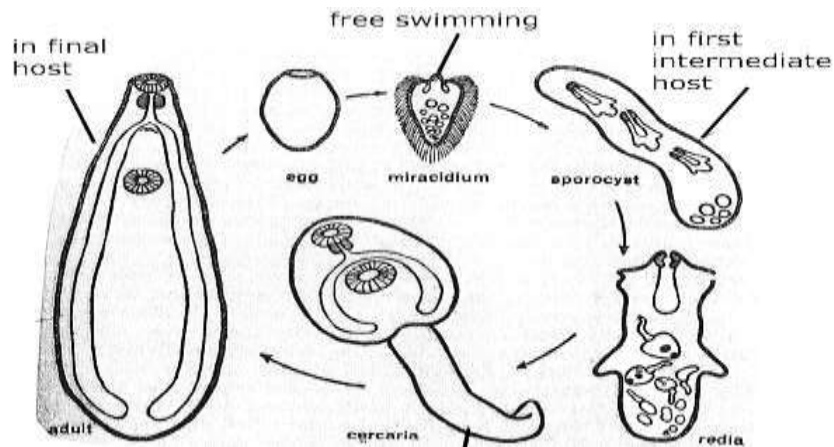
Life Cycle and Hosts:

Parasitic helminthes are highly modified compared to free-living helminthes. They often lack sense organs such as eyes, and may even lack a digestive system. Their reproductive system, however is often complex, which ensures infection of new hosts. Some flukes can produce 25,000 eggs per day.

Adult helminthes may be Dioecious; male reproductive organs are in one individual, and female reproductive organs are in another. In those species, reproduction occurs only when two adults of the opposite sex are in the same host. Adult helminthes may also be Monoecious, or Hermaphroditic (one worm has both male and female reproductive organs). Two hermaphrodites may copulate and simultaneously fertilize each other.

Stages of life cycle in Platyhelminthes:

- 1- Eggs: produced by adult worm, small circle to oval shape, average 100 μm , ova may have operculum or un-operculated, mature ovum contains first larval stage called miracidium.
- 2- Miracidium: is ciliated, and its prominent internal features include eyespots, various penetration glands, and different excretory cells and tubules.
- 3- Sporocyst: simple, tubular or branched germinal sacs.
- 4- Redia: tubular germinal sacs, which possess an oral sucker and a simple digestive system, a birth pore, and small moving appendages. This stage either contains another generation of redia, called daughter redia, or contains the next stage, cercaria.
- 5- Cercaria: resemble small adults, with a similar body shape, digestive system. They have only the essentials of their reproductive systems and a tail (which takes on numerous forms and is useful for identification.)
- 6- Metacercaria: usually resemble the cercariae from which they developed, without the tail, and may be enclosed in a clear cyst.



Clinical diagnosis methods of helminthes:

Parasitic infections are usually diagnosed from samples of faeces, urine, blood and tissues; it can be direct or indirect.

Direct identification:

- 1- Evidence of intestinal parasitism, apart from the general clinical signs, is obtained from faecal examination. Parasite concentration in faeces by flotation is used for the identification of helminth eggs.
- 2- Urine examination of urine sediment is used mainly for the identification of *Schistosoma* eggs.
- 3- Blood testing is used to identify the various stages of blood parasites and is routinely applied to diagnose malaria, trypanosomiasis and most types of filariasis.
 - a- Thin blood films are useful for studying morphological changes of blood cells and blood parasites.
 - b- Thick blood films contain 6 to 20 times as much blood per unit area as thin films. The thick film is suited for rapid diagnosis of parasitaemia that is too low to be detected with thin films.
- 4- Tissue recovery of helminths from biopsy material is often an important aid for diagnosis. Lymph node, spleen, liver, lung, bone marrow or spinal fluid biopsies are used to diagnose a variety of worms.

Indirect identification: indirect methods, must be used if the parasite density in the specimen is below the sensitivity of the method employed, or if the parasite cannot be directly demonstrated due to the life cycle in the host and usually include immunological tests, such as, Complement fixation test (CFT), Indirect fluorescent antibody test (IFAT), Radioimmunoassay (RIA), Enzyme Linked Immunosorbent Assay (ELISA), Rapid card agglutination test (CAT).

Nucleic acid-based diagnosis: The use of nucleic acid probes in the diagnosis of parasitic infections, is based on the fact, that every organism carries unique DNA sequences. This technique proved specificity and sensitivity of diagnosis, such as Polymerase Chain Reaction (PCR).

Intermediate host: The host that carry the immature reproductive (non-sexual) stage of the worm. Human can serve as intermediate host for a few worms.

Definitive host: The host that carry the mature reproductive (sexual) stage of the worm. Human can serve as the definitive host for most of worms, such as, beef, pork, and fish tapeworms.

Infective stage: The larval stage of the worm, which attacks the final host to complete its life cycle.

Helminthes Classification:

- 1- Phylum Platyhelminthes, Trematodes and Cestods.
- 2- Phylum Nematelminths, Nematodes.

Phylum Platyhelminthes (Flatworms) general characteristics:

- 1- Bilaterally symmetrical, dorsoventrally flattened, triploblastic and acoelomate.
- 2- Body shape generally worm-like but varies from moderately elongated shape to long flat ribbons and leaf-like.
- 3- Small to moderate in size varying from microscopic to extremely elongated forms measuring up to the 10-15 meters.
- 4- White, colorless, some derive color from the ingested food.
- 5- Anterior end of the body is differentiated into the so called head.
- 6- Presence of great variety of adhesive secretions, organs of attachment and adhesion (hooks and suckers).

- 7- Parasitic trematodes and cestodes, epidermis is lacking and the body is covered with cuticle.
- 8- Body is smooth due to lacking of endo and exoskeleton.
- 9- Body space between the various organs is filled with a mesenchyme usually called parenchyma.
- 10- Digestive system, if present, is incomplete.
- 11- Sexes are united (hermaphrodite) with very few exceptions.
- 12- Reproductive system is highly evolved in most of the forms.

Classification of Platyhelminthes:

First: Class: Turbellaria: Most are free-living.

Second: Class: Trematoda المخرمات (having pores), general characteristics:

- 1- Ectoparasitic or endoparasitic forms, commonly called flukes.
- 2- Body shape usually Leaf-like, dorsoventrally flattened.
- 3- Body wall without epidermis and cilia, most are hermaphrodite.
- 4- Body undivided and covered with a cuticle, most are hermaphrodite.
- 5- Well-developed suckers usually present, ventral sucker sometimes termed the acetabulum

Monostome is used to describe worms with one sucker (no ventral sucker) *e.g. Notocotylus*.

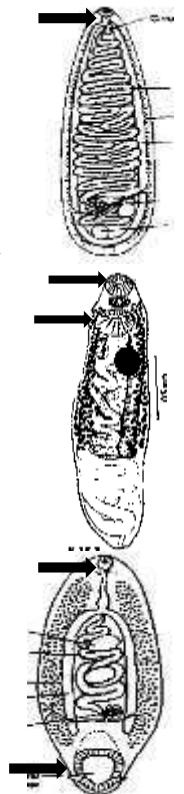
Distomes is used to describe worms with two suckers (oral and ventral) *e.g: Fasciola*.

amphistomes is used to describe worms with oral sucker and an acetabulum at the posterior end of the body, *e.g: Paramphistomum*.

- 6- Digestive tract incomplete consisting of mouth, pharynx and two forked or many branched intestine; anus absent.
- 7- Protonephridia excretory system consisting of flame cells.

Order- Monogenea: وحيدة المنشأ

- 1- Ecto-or endoparasitic worms on vertebrates.
- 2- Oral sucker either weak or absent.
- 3- Anterior end provided with a pair of adhesive structures.
- 4- Posterior end provided with an adhesive disc (opisthaptor)
- 5- Free- swimming ciliated larva called **onchomiracidium**



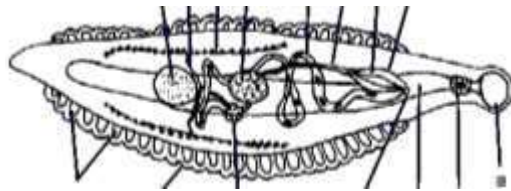
- 6- Only one host in life cycle. *e.g. Gyrodactylus*



Monogenea: *Gyrodactylus*

Order-Aspidobothria:

- 1- Endo-parasites in the gut of fish and reptiles.
- 2- Oral sucker is absent.
- 3- The anterior end without an adhesive structure.
- 4- Life cycle simple, no alternation of hosts. *e.g. Aspidogaster*



Aspidobothria: *Aspidogaster*

Order-Digenea ثنائية المنشأ :

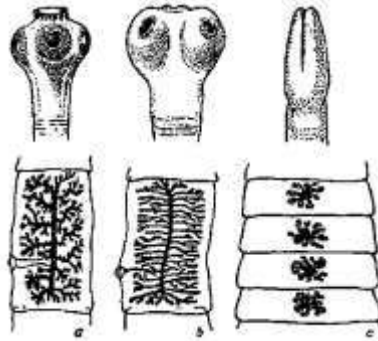
- 1- Endo-parasites of vertebrates and invertebrates.
- 2- Mostly with two suckers without hooks.
- 3- Life cycle is complicated involving many larval stages.
- 4- One or more intermediate hosts in life cycle.

Third: Class: Cestoda الشريطيات:

- 1- Endo-parasites in the intestine of vertebrates, called tapeworms.
- 2- Body without epidermis and cilia but covered with cuticle.
- 3- Body is divided into few to many segments (proglottids).
- 4- Anterior end (scolex) is provided with adhesive structures (hooks or suckers) except in subclass Cestodaria.
- 5- Mouth and digestive tract totally absent.
- 6- Excretory system consists of protonephridia.
- 7- Nervous system usually comprises a pair of ganglia and two lateral longitudinal nerve cords.

- 8- Each segment contains one or two sets of complete hermaphroditic reproductive system.
- 9- Life cycle complicated usually involving two or more hosts.
- 10- Embryos possess hooks.

Cestoda worm



Parasitic adaptation: Parasitic Fitness of the parasite to its environment. It is the characteristic which results in suitable and convenient morphological and functional correlation between an organism and its environment.

A- Morphological adaptations: تأقلم مظهري

- 1- Body covering: thick tegument frequently provided with scales affords suitable protection to the parasite. This thick protoplasmic layer is continually renewed by mesenchymal cells forming it.
- 2- Organs of adhesion: for a firm grip on/in the host's body, some special organs of adhesion are needed. Flatworms are variously armed with suckers, hooks and/or spines.
- 3- Organs of locomotion: food of parasite comprises readily available and digested/ semi digested food of the host. Elaborate organs of nutrition not needed. They have an incomplete gut and in most cases a suckorial pharynx for sucking food. In cestodes, worms freely bathes in digested food of host, which is absorbed directly, thus, total absence of alimentation in tapeworms.
- 4- Neurosensory system: need for quick & efficient "response to stimuli" is associated with free active life and not with a quiet parasitic life in a safe environment. In parasitic worms therefore, there is preferred

reduction of nervous system and a total absence of sense organs but the free-living miracidium possesses eyespot.

5- Reproductive system: best developed system in helminth parasites, designed and preferred to meet the need for tremendous egg production. Parasitic flatworms with a few exceptions (like *Schistosoma*) are monoecious (hermaphrodite). Hermaphroditism is of distinct advantage to the parasite because:

- It ensures copulation even when a few individuals are present.
- After copulation, both individuals lay eggs, doubling the rate of production.

B- Physiological adaptations: تأقلم وظيفي

1- Protective mechanism: inside the alimentary canal the parasites have to protect themselves from the action of digestive juices of host. Tapeworms accomplish this by:

- Stimulating walls of gut to secrete mucus, which then forms a protective clothing around parasite.
- Secreting antienzymes to neutralize the digestive enzymes of host.
- Continually renewing their protective body covering, *e.g.* tegument.

2- Anaerobic respiration: environment in gut and bile ducts is devoid of free oxygen. Flatworms inhabiting these places, therefore, they respire anaerobically by breaking down glycogen.

3- Osmoregulation: osmotic pressure of endoparasite's body fluids, especially in case of trematodes is almost the same as that of host. In intestinal tapeworms, osmotic pressure is little higher, this permits ready absorption of host's digested food by tapeworms.

4- High fertility: eggs produced by a parasitic flatworm face a very uncertain future while passing through the complex life cycle. Consequently, many worms produce eggs in millions and their reproductive organs are very well-developed.

Phylum Platyhelminthes

Platyhelminthes can be divided, according to the worms' habitat in the final host, into:

- 1- Liver flukes مخرمات كبدية
- 2- Intestinal flukes مخرمات معوية
- 3- Lung flukes مخرمات رئوية
- 4- Blood flukes مخرمات دموية

First: Liver flukes

***Fasciola hepatica* (sheep liver fluke) de Brie, 1883**

***Clonorchis sinensis* (Oriental liver fluke) James McConnell, 1847**

***Dicrocoelium dendriticum* (Lancet liver fluke) Rudolphi, 1819**

Fascioliasis or liver rot is a disease caused by two species of parasitic flatworms or trematodes that mainly affect the liver. It belongs to the group of water borne and foodborne trematode infections and is a zoonosis, meaning an animal infection that may be transmitted to humans.

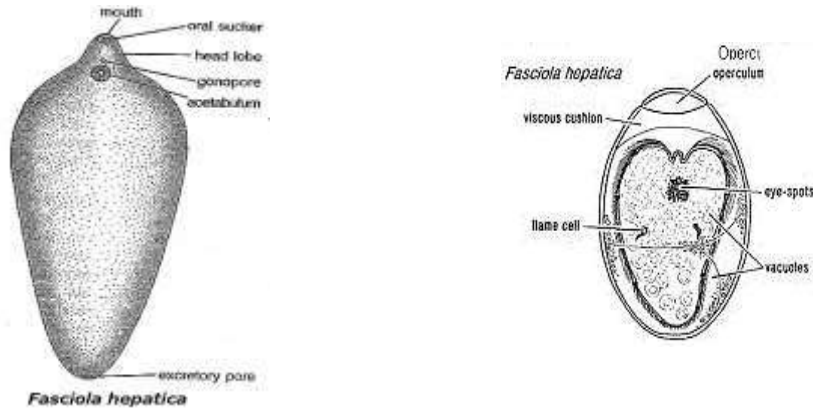
Human cases occurred occasionally but are now increasingly reported from Europe, the Americas and Oceania (where only *F. hepatica* is transmitted) and from Africa and Asia (where the two species overlap). WHO estimates that at least 2.4 million people are infected in more than 70 countries worldwide, with several million at risk. No continent is free from fascioliasis, and it is likely that where animal cases are reported, human cases also exist.

1- *Fasciola hepatica* (sheep liver fluke)

Morphology:

Adult Worm: averaging 30 mm in length and 13 mm in width, *F. hepatica* is one of the largest flukes in the world. The adult worm has a very characteristic leaf shape with the anterior end being broader than the posterior end and an anterior cone-shaped projection. The fluke possesses a powerful oral sucker at the end of the anterior cone and a ventral sucker (acetabulum) at the base of the cone, which allow it to attach to the lining of the biliary ducts.

Each worm possesses ovaries and testes, which are highly branched and allow for individual flukes to produce eggs independently.

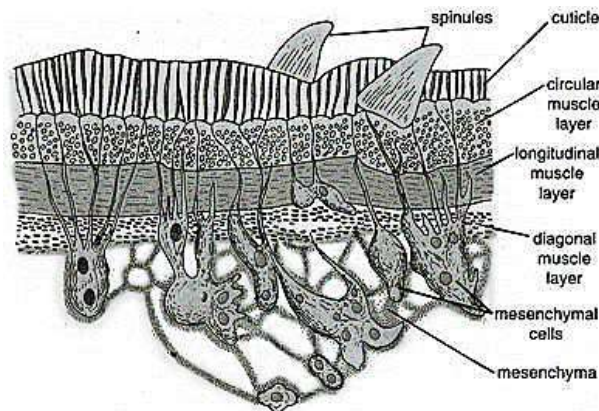


The Egg: is operculated and average 140 μm in length and 75 μm in width, egg of *F. hepatica* is un-embryonated when released.

Body wall: The wall of *F. hepatica* lacks a cellular layer of epidermis. However, it consists of a thick layer of cuticle made of a homogeneous layer of scleroprotein to protect the fluke from the juices of the host, a thin basement membrane.

Smooth muscle layers consist of an outer layer of circular muscle fibers, middle layer of longitudinal muscle fibers and an inner layer of diagonal muscle fibers.

Mesenchyme below the muscles with numerous loosely arranged uninucleate and binucleate cells with syncytial network of fibers having fluid filled spaces. Mesenchyme helps in the transport of nutrients and wastes substances.



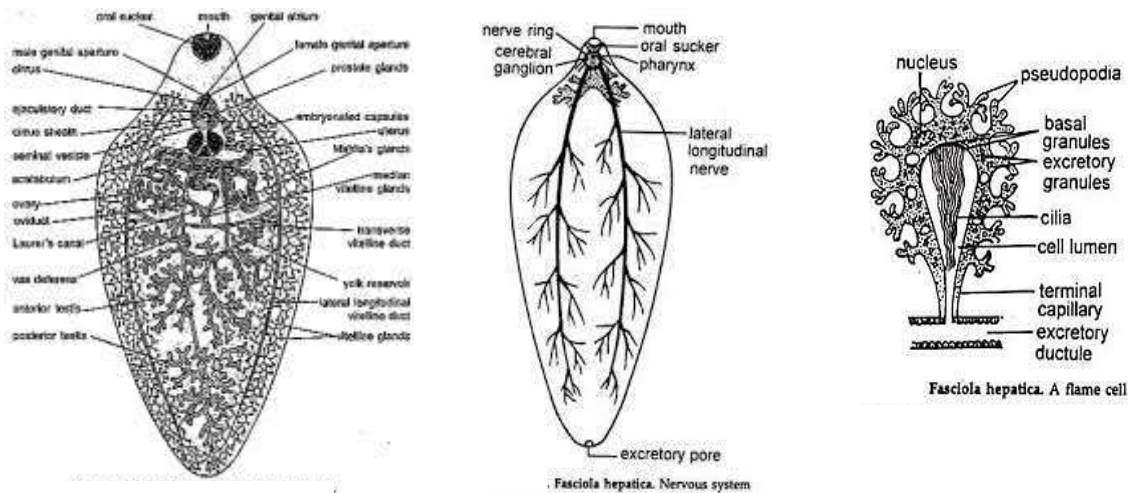
Digestive system: The alimentary canal of *F. hepatica* is incomplete. The digestive system begins with mouth surrounded by the oral sucker, highly muscular pharynx, esophagus and intestine but does not terminate in anus that is why it is referred as incomplete. The intestine immediately forks to form right and left limbs or branches that run along both side of the body up to the posterior extremity and terminate blindly. These branches of the intestine are called intestinal caeca.

Digestive system from the mouth up to the esophagus is lined by cuticle. This region of the alimentary canal is the fore gut region that serves as efficient suctorial apparatus. The intestine is lined by columnar epithelial cells that are endodermal in origin. Numerous secretory gland cells surrounded by a thin muscular layer consisting of circular and longitudinal muscle fibers are present in the caecal epithelium.

The fluke often migrates into the bile ducts and the capillaries of the host for nourishment. It feeds on blood, lymph, inflammatory exudates and bile juice which it sucks from the wall of the host's bile passages.

Excretory system: The excretory system is concerned with excretion as well as osmoregulation. It consists of a large number of flame cells or protonephridia connected with a system of excretory ducts to the excretory pore at the posterior end. Flame cells are irregular in shape bulb like bodies; each has a thin elastic wall with pseudopodia like processes and nucleus. An intracellular cavity has many long cilia arising from basal granules. The cilia vibrate like a flickering flame.

Nervous system: A nerve ring surrounds the esophagus, it has a pair of cerebral ganglia and a ventral ganglion below the esophagus, and small nerves are given out anteriorly from the ganglia. Posteriorly three pairs of longitudinal nerve cords arise the ganglia (dorsal, lateral and ventral nerve cords), the lateral nerve cords are best developed, and they run to the posterior end and give out many small branches. Sense organs are lost in adult fluke.



Respiration: Mode of respiration is anaerobic or anoxybiotic. Glycogen is metabolized to carbon dioxide and fatty acids releasing energy in the form of heat. The carbon dioxide, thus, produced is diffused out through general body surface and the fatty acids are excreted through the excretory system.

Reproductive system: *Fasciola hepatica* is hermaphrodite. The gonads are well developed and the male and female genital ducts open into a common chamber, the genital atrium. It is situated anteriorly in the body and opens to the exterior through the common gonopore, located ventrally in front of the acetabulum.

Male Reproductive Organs:

- a- **Testis:** greatly ramified, in the middle of the body, one behind the other.
- b- **Vasa deferentia:** A narrow delicate duct, the vas deferens, emerges out from each testis and runs forward to meet the fellow of opposite side forming the common sperm duct just below the ventral sucker.
- c- **Seminal vesicle:** large muscular pear-shaped sac, lies in front of ventral sucker.
- d- **Ejaculatory duct:** fine convoluted tube from the seminal vesicle runs forward in a zigzag fashion through the cirrus to open into the genital chamber through the male genital pore.
- e- **Cirrus and cirrus sac:** The cirrus or penis is a muscular cylindrical structure traversed internally by the passage of ejaculatory duct. It can be pushed out

and drawn in through the genital pore and thus helps in copulation. The cirrus and the seminal vesicle both are enclosed in a bag-like cirrus sac.

f- Prostate glands: unicellular prostate glands around the ejaculatory duct.

Female Reproductive Organs:

a- Ovary: large, highly branched tubular structure on the right, in front of testes.

b- Oviduct: short, narrow and convoluted duct runs down ward to join the uterus.

c- Uterus: long wide and highly convoluted tube that extends up to the genital atrium, opening into it through the female genital aperture, close to male genital pore on the left side. It contains a large number of capsules containing fertilized eggs.

d- Mehlis gland: also called shell glands but they do not play any role in shell-formation, surrounding the base of the oviduct, function of this gland includes secretion helps in lubricating uterus for smooth passage of eggs and in activating sperms.

e- Laurer's canal: The Laurer's canal arises from the oviduct and acts as a sperm duct. It develops a temporary opening on the dorsal body surface during breeding season. It may serve as vagina.

f- Vitellaria (Vitelline glands and vitelline ducts): provide eggs with yolk.

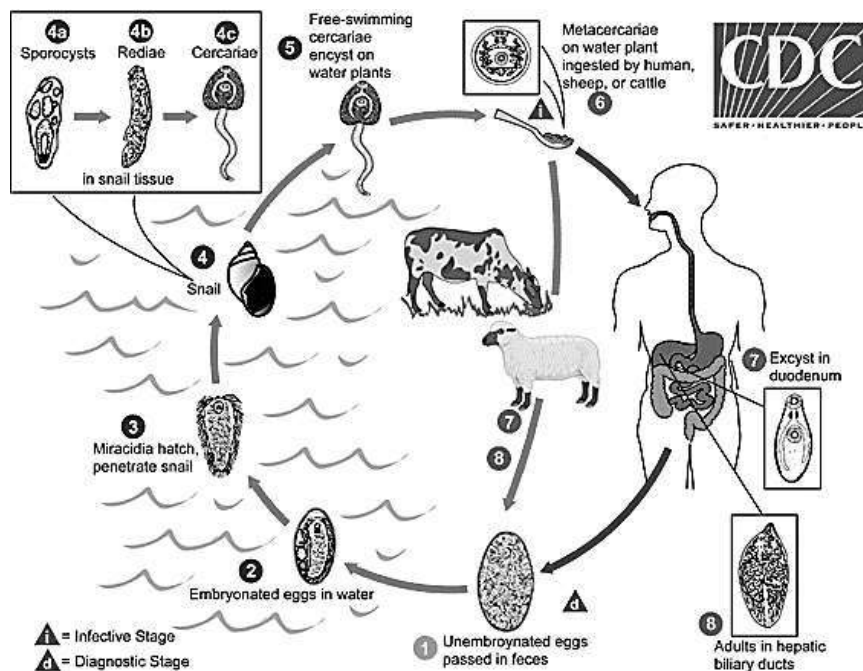
Life cycle of *Fasciola hepatica*:

Unembryonated eggs pass through feces, following the passage of the eggs in the stool, miracidia develop within 2 weeks, escape from the eggs, and infect the *Lymnaea* snail, which acts as the first intermediate host penetrated by the miracidia.

Inside the snail, miracidia reach the digestive gland and within 14 days, the second larval stage is produced, called sporocyst. Further development occurs when the germ balls in the sporocyst give rise to the next generation of redia. *F. hepatica* has two generations of redia, mother and daughter redia. Active daughter redia are eventually transform to the cercaria, which they leave the snail to the outer environment.

Cercaria are released into fresh water where feces is dumped or runs into the water. There, they encyst and form metacercariae on freshwater vegetation called watercrass, which is considered the second intermediate host.

Humans and other mammals are infected after eating the contaminated vegetation. The metacercariae excyst in the duodenal portion of the intestine and the larvae penetrate the intestinal wall and enter the gallbladder and bile ducts of the human host. The adult worms attach themselves in the large bile ducts and the gallbladder of humans rather than in the intestines as other parasites do, but eggs are passed from the bile duct into the intestine and are excreted in feces.



Symptoms and signs:

After the larvae are ingested with contaminated food or water, a symptomless incubation period starts, lasting for a few days to a few months. This is followed by an acute and a chronic clinical phase:

Acute phase: The acute phase, lasting 2-4 months, begins when the immature worms penetrate the intestinal wall and the peritoneum, the protective membrane surrounding the internal organs. From here, they puncture the liver's surface and eat their way through its tissues until they reach the bile

ducts. This invasion kills the liver's cells and causes intense internal bleeding. Typical symptoms include fever, nausea, a swollen liver, skin rashes and extreme abdominal pain.

Chronic phase: The chronic phase begins when the worms reach the bile ducts, where they mature and start producing eggs. These eggs are released into the bile and reach the intestine, where they are evacuated in faeces, thereby completing the transmission cycle. Symptoms include intermittent pain, jaundice and anaemia. Pancreatitis, gallstones and bacterial super-infections may also occur. Patients with chronic infections experience hardening of the liver (fibrosis) as a result of the long-term inflammation.

In animals, *F. hepatic* is responsible of a disease called “liver rot”, which is the main infection in animals, this occurs by mechanical and toxic destruction of liver tissue by passage of immature worms necrosis, fibrosis, hepatitis, and hepatomegaly. Obstructive jaundice also occurs when the adult worms reside in the bile ducts which leads to irritation and thickening of the ducts and stone formation.

Laboratory diagnosis:

The characteristic eggs of *F. hepatica* in feces. Entero-test string procedure may also be helpful. The Entero-test string procedure is a simple and non-invasive method useful in sampling duodenal fluid. Eggs are recovered from duodenal aspirates containing bile fluid and can be diagnosed as *F. hepatica* eggs reside exclusively in the bile duct and the gallbladder. Serological methodology is also available for early diagnosis of the liver fluke infection.

Treatment and prevention: Bithinol, which is a halogenated phenol, is used for treatment of the infection. Triclabendazole is also effective as treatment for this worm. Prevention of infection is accomplished by avoiding raw vegetation growing in watery environments in endemic regions. Adherence to good sanitary practices where raw human sewage is properly treated and disposed of will also prevent infection.

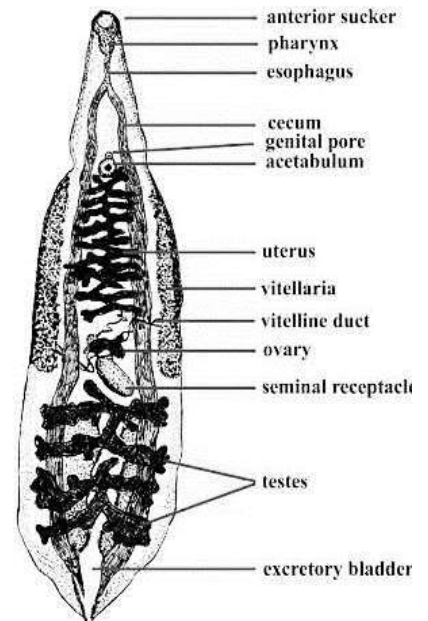
2- *Clonorchis sinensis* (Oriental liver fluke)

Geographical distribution: Asia

Disease: Chlonorchiasis

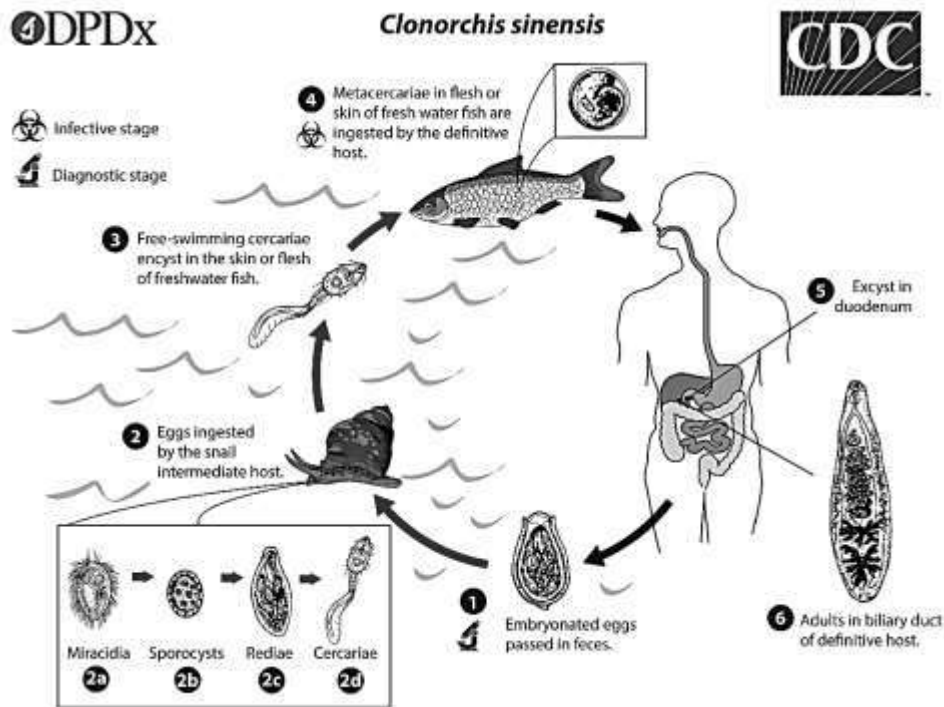
Morphology: flat, elongated, lancet-shape worm, 11-20 mm length, 3-5 mm width. The digestive tract consist of a small pharynx behind oral sucker, a short esophagous, and two ceca that terminate blindly. Deeply lobed two testes that are found at the posterior end, one in front the other.

Ovary lies in fron of the testes and it is trilobed, vitelline glnds on both sides of the worm concentrated in the middle of the body worm. Convolutud uterus rising from the ootype and terminates by the genital atrium.



Life cycle:

Eggs are discharged in the biliary ducts and in the stool in an embryonated state. Eggs are ingested by a suitable snail intermediate host, *Bulinus* or *Bithynia*. Eggs release miracidia, which go through several developmental stages (sporocysts, rediae, and cercariae). The cercariae are released from the snail and, after a short period in water, they come in contact and penetrate the flesh of freshwater fish (family cyprinidae), where they encyst as metacercariae. Infection of humans occurs by ingestion of undercooked, salted, pickled, or smoked freshwater fish. After ingestion, the metacercariae excyst in the duodenum and ascend the biliary tract. Maturation takes approximately one month. The adult flukes (measuring 10 to 25 mm by 3 to 5 mm) reside in small and medium sized biliary ducts.



Pathogenicity & symptoms: Adult flukes inhabit the distal bile ducts with epithelial proliferation, surrounding inflammatory reaction and ascending cholangitis. Secondary bacterial infection with jaundice, septicaemia, and eosinophilia. Some cases are asymptomatic.

Diagnosis: microscopic examination of ova in feces or in duodenal aspiration.

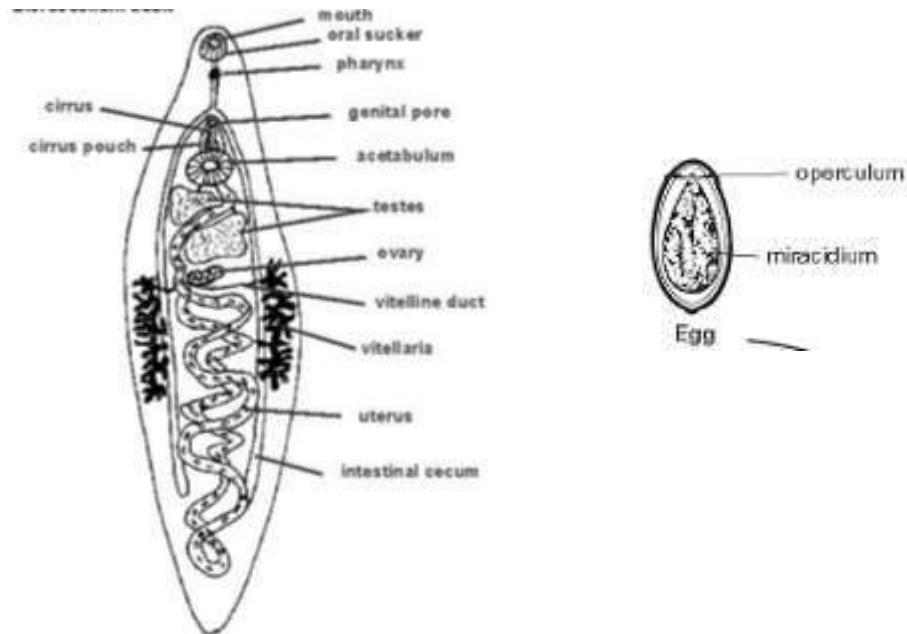
Treatment: Praziquantel but heavy infection may require surgery.

3- *Dicrocoelium dendriticum*, Lancet liver fluke

Common worm of bile passages of sheep and herbivorous and ruminant mammals, and humans, causing dicrocoeliasis. It is widespread in Europe, Asia and Africa, lesser extent in north and South America.

Adult morphology: adult worms reside in the smaller bile ducts; it is lancet shape, flat, thin and transparent. *D. dendriticum* relatively small, measuring 5 to 15 mm by 1-2 mm and covered with a smooth cuticle. The most conspicuous features of the internal anatomy are the position of the two testes anterior to the ovary in the anterior half of the body, and distribution of the major portion of the long uterine coils in the median field of the posterior half of the body.

The egg: eggs are asymmetrical, ovoidal shape with thick shell, dark brown in color, they have a broad convex operculum and measure about 45 micron. The egg usually contains a mature miracidium when released from the definitive host.



Life cycle:

Ruminants such as cows and sheep are usually the definitive host, but humans and other herbivorous mammals can also serve as definitive hosts through ingestion of infected ants. Lancet liver fluke has an indirect life cycle with two intermediate hosts, a snail and an ant. The eggs shed by adult flukes reach the host's gut with the bile and are expelled with the feces. Once outside the host, a terrestrial snail *Cionella* ingests eggs.

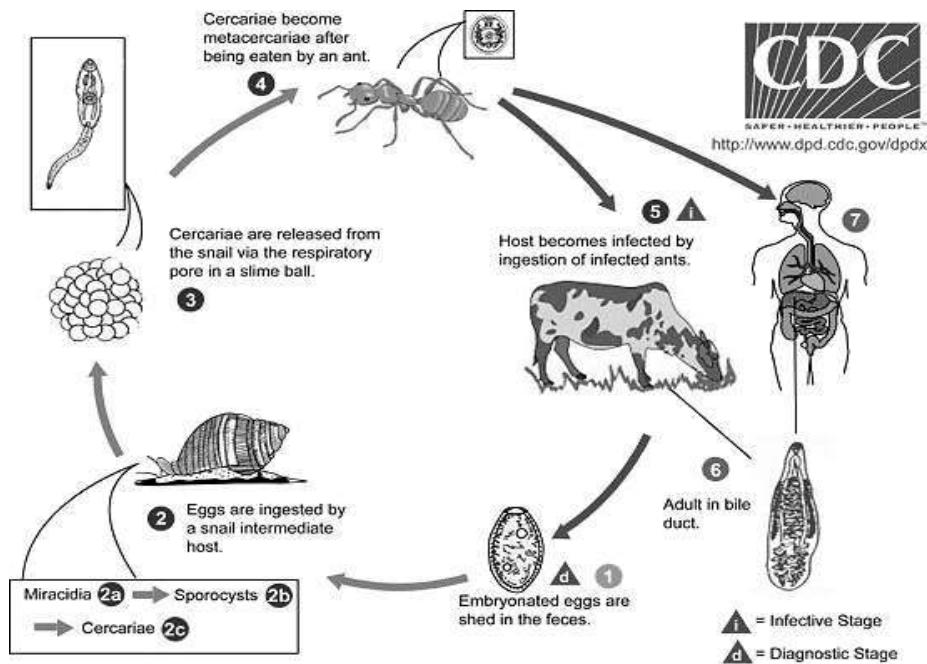
Inside the snail, miracidia hatch out of eggs in the gut of the snail and develop into sporocysts, which on their turn multiply asexually, each one producing about 100 daughter sporocysts (no redia stage). Each daughter sporocyst can produce up to 60 cercaria in 3-4 months. Accumulation of cercaria in the snail cause irritation, which results in expelling them in the form of slime balls that adhere to the vegetation, each slime ball, may contain about 100 cercaria.

Silky ants or *Formica fusca* act as the second intermediate host, these ants eat the slime balls on the vegetation. Inside the ants, most cercaria continue

developing to metacercariae that are infective for the final host (cattle, sheep, goats and humans).

Metacercariae remain in the hemocoel of the ant but few of them migrate to the sub-esophageal ganglion of the ant and manipulate its behavior by acting on the nerve cells. Towards the evening, instead of following the rest of the ant colony, the manipulated ant climbs on top of blade of grass and remains there the whole night through until dawn. Final host can then ingest the infected ants during feeding on grass in early morning grazing.

Once the final host ingests the infected ant, the metacercariae are released in the gut of the host and migrate to the liver through the common bile ducts (they do not migrate to the liver tissue as in *Fasciola*). Metacercariae complete the development to adults and start producing eggs in 8-12 weeks. Adult worms feed on bile but not liver tissue.



Pathogenicity & symptoms:

Most infections have no symptoms or only slight ones, in case of heavy infections (up to 50,000 flukes in one animal) the bile duct become irritated and distended. Chronic infection can cause blood loss, anemia and end with cirrhosis. However, infection with *Dicrocoelium* is usually less harm than *F. hepatica*. Economic damage is mostly due to condemnation of the livers at slaughter and to reduced productivity of affected livestock.

Laboratory diagnosis:

Detection of eggs in the feces or by identification of the flukes after necropsy. However, since the eggs are passed to the intestine only when the gall bladder is emptied, a negative fecal egg count is not conclusive, i.e. there can be false negatives.

Prevention and control of *Dicrocoelium*:

The most important preventative measure is to keep the snail population as low as possible. The snails that act as intermediate hosts are terrestrial, but need humidity for development and survival. Effective drainage or anything else that keeps the pastures dry will reduce the snail population. Triclabendazole, Netobimin and praziquantel (20 mg/kg) are the drug of choice for infected animals.

Intestinal flukes

1- *Fasciolopsis buski* (Giant intestinal fluke) George Busk, 1843

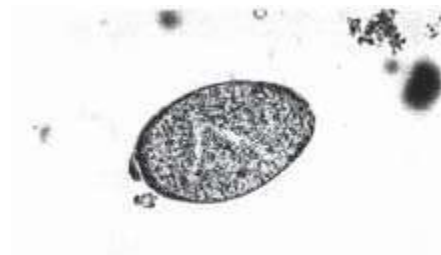
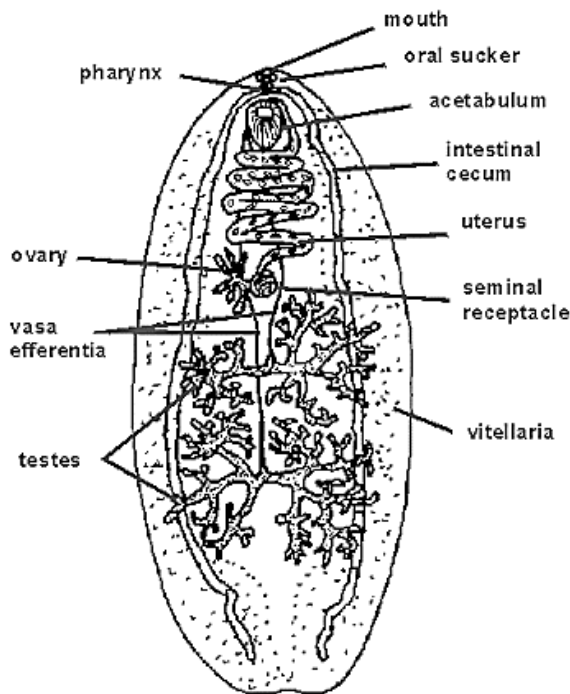
2- *Heterophyes heterophyes* (Smallest fluke of man) T. M. Bilharz, 1851

3- *Echinostoma revolutum*, Frolich- 1802.

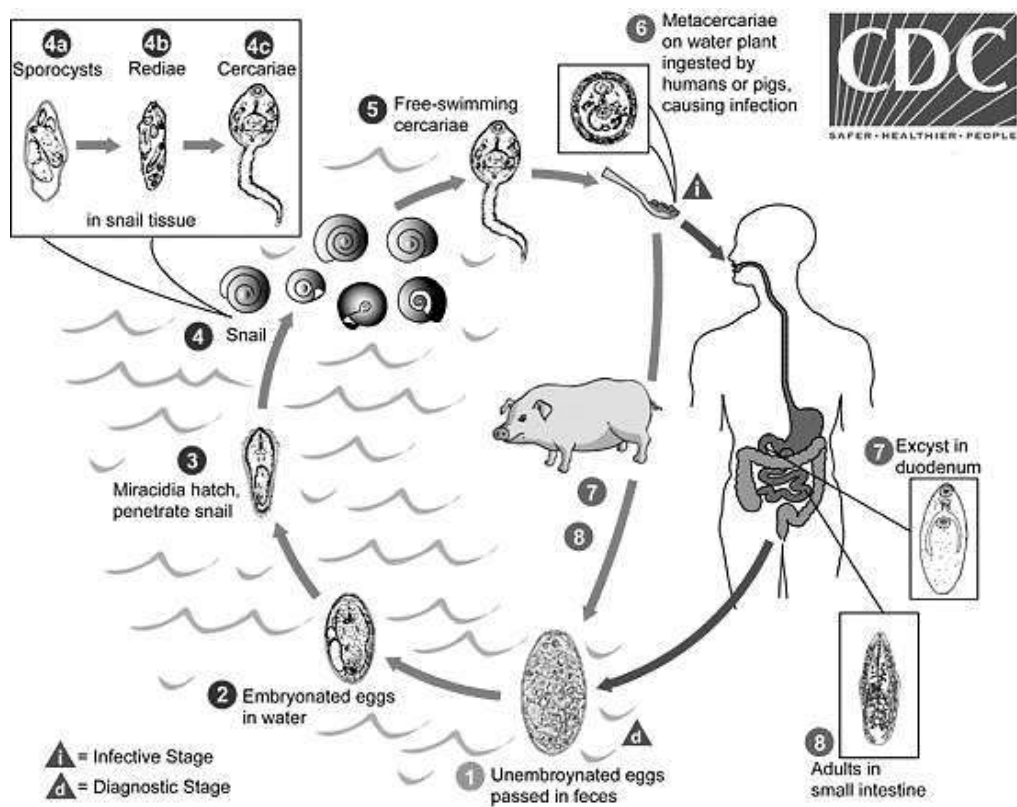
4- *Paramphistomum cervi* (Livestock rumen fluke)

***Fasciolopsis buski*:** Largest parasitic trematodes of man, it also infect sheep, cattle and pigs. causes fasciolopsiasis, geographical distribution: Asia, specially China, India, Thailand and Indonesia.

Morphology: Thick, fleshy, ovate measures 2.0-7.5 cm length by 0.8-2.0 cm width and, oral sucker is much smaller than ventral. Intestinal tract unbranched (unlike *F. hepatica*) Two highly branched testes one behind the other, branched ovary in the middle of the body to the right of the midline. Vitelline glands extend from the level of ventral sucker along both laterals to meet at the posterior end. From the only uterus follows a convoluted course to open into the genital atrium. Eggs are immature when released and they are indistinguishable from eggs of *F. hepatica*.



Life Cycle: *F. buski* normally lives in the small intestine of man or animals, its life cycle resembles that of *F. hepatica*. The miracidium, after escaping from the shell, swim in the water and it penetrates a suitable snail host of the genus *Segmentina*, within the snail it metamorphoses successively into sporocyst, mother rediae, daughter rediae and cercariae, which leaves the snail and encysted on aquatic plants to become metacercariae. Metacercariae are ingested by man or animal when infested plants are eaten raw. In duodenum the cyst wall is dissolved by the digestive juices and excysted metacercaria attaches itself to the mucosa of the upper intestine, where it becomes an adult worm.



Pathogenicity & symptoms: a localized inflammation at the site of attachment with hemorrhages and occasional abscess. Eosinophilia, diarrhea, abdominal pain, anorexia, nausea, and vomiting. In heavy infection, there is absorption of toxic products, resulting in edema. The skin is harsh and dry.

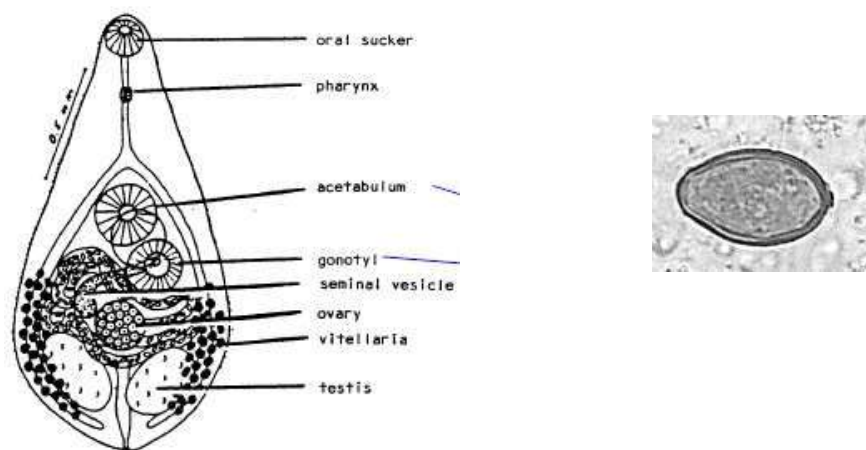
Diagnosis: eggs in feces.

Treatment: Praziquantel.

Heterophyes heterophyes: This trematode worm occurs in several regions of East Africa, Egypt, and South Europe. About 30 millions of humans are infected besides dogs, cats, and some other fish-eating mammals. Adults live in the small intestine.

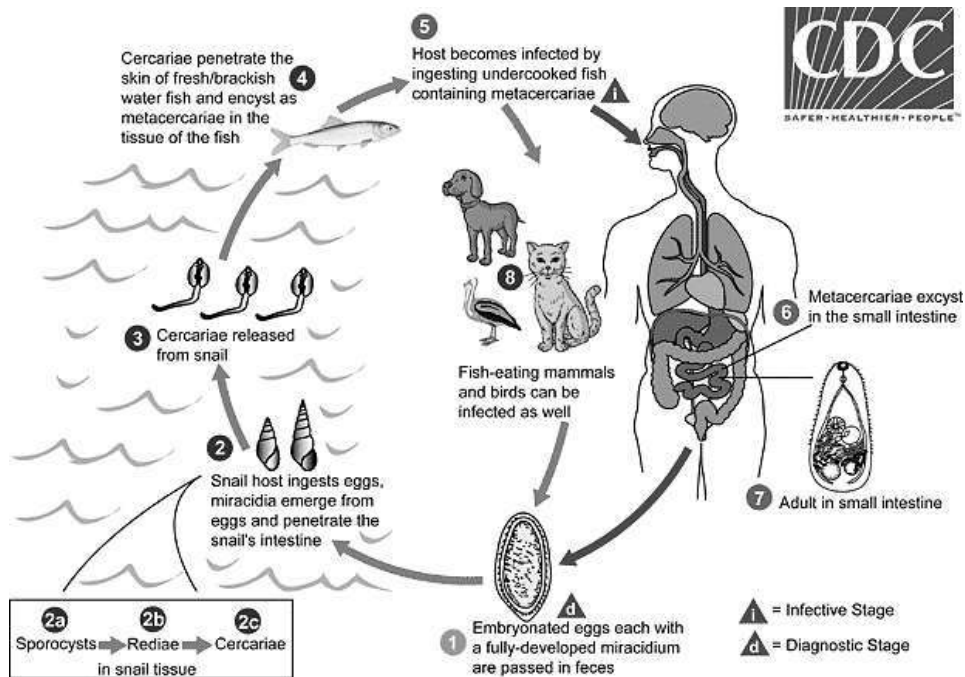
Disease: Heterophyiasis

Morphology: All *Heterophyes* species are small trematodes, under 2 mm long. Body has a pyriform shape and tiny spikes cover their outer surface. Oral sucker is much smaller than ventral one and pharynx is long and well developed. A non-adhesive genital sucker or gonotyle lies close left the ventral sucker. Two intestinal ceca, which terminate blindly. Two ovoid testes lie in the midline, long, coiled uterus opens beside the male pore in genital sucker. The vitellaria consist many follicles on each side.



Eggs: small, uperculated, yellowish brown with thin-shell. Eggs are embryonated when released contains fully developed miracidium.

Life cycle: ova are ingested by the first intermediate hosts snail, *Pirenella conica*. The miracidium develops successively into sporocysts, two generations of rediae, then cercariae. After leaving the snail, the cercariae encysts on the scales, tail, gills, muscles of the second intermediate host the fish, *Mugil cephalus*, infected fish are eaten raw or imperfectly cooked (سمك (الفسيح في مصر) so the metacercaria escapes from the cysts and develops into the adult worm in the small intestine. Growth is rapid, mature ova being formed in 7-8 days after infection.



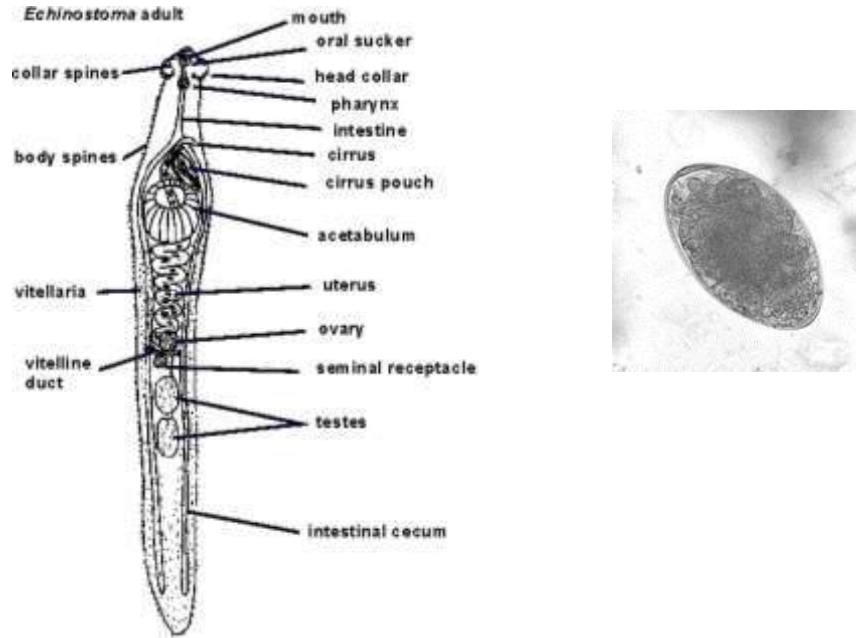
Pathogenicity & symptoms: Mild inflammatory reaction, abdominal pain, diarrhea, anorexia and nausea. In heavy chronic infection, ova may reach heart and brain.

Diagnosis: ova in feces.

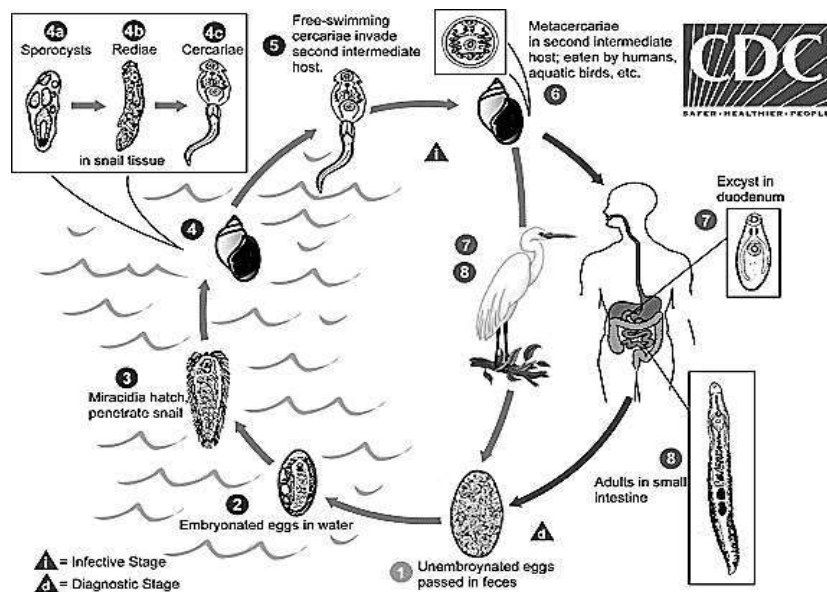
Treatment: Praziquantel and Niclosamide.

Echinostoma revolutum: worms found in America, Europe and Asia causes echinostomiasis in aquatic birds, carnivores and humans. This worm is much longer than wide, it measures an average of 6-8 mm long by 2 mm width, long is three times the width. The morphological characteristic feature is the cephalic collar of spines, the number of spines depends on the species, adult worms reside in the small intestine.

Eggs: Eggs size varies 80-135 µm long by 55-80 µm wide. They have an unclear operculum and the abopercular end is often thickened. The larger eggs are very similar to *Fasciola* and *Fasciolopsis*. Eggs are passed unembryonated in feces.



Life Cycle: Unembryonated eggs are passed in feces and develop in the water. The miracidium takes on average 10 days to mature before hatching and penetrating the first intermediate host, the snail *Lymnaea*. The intramolluscan stages include a sporocyst, two generations of rediae, and cercariae. The cercariae leave the snail and encyst as metacercariae after penetrating the second intermediate host, another snail, fish or tadpoles. The definitive host becomes infected after eating infected second intermediate hosts. Metacercariae excyst in the duodenum and adults reside in the small intestine.



Pathogenicity & symptoms: Catarrhal inflammation (increasing blood flow to the mucosa and edema) often occurs due to the penetration of the sharp-spined collar into the intestinal mucosa. In addition, nausea, vomiting, diarrhea, fever and abdominal pain may occur.

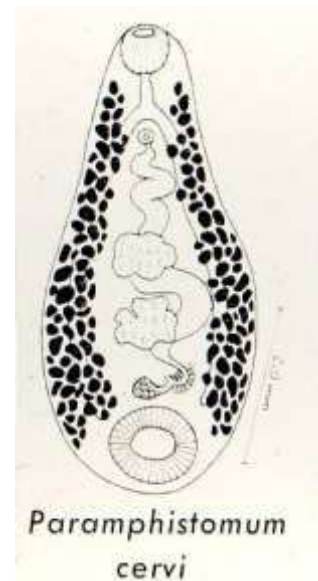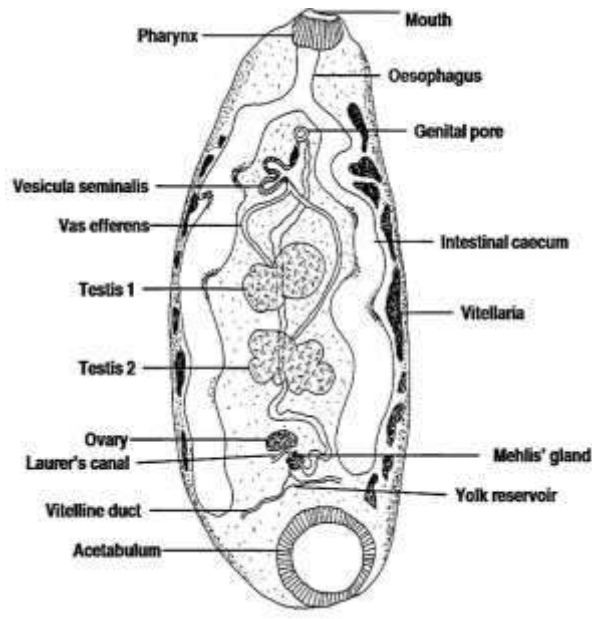
Diagnosis: Eggs in feces.

Treatment: Mebendazole and albendazole.

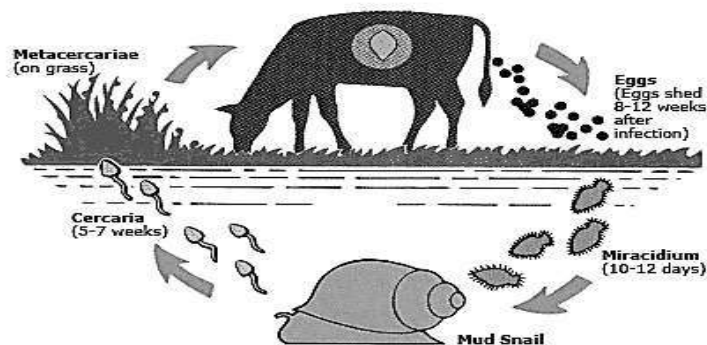
***Paramphistomum cervi*:** The livestock rumen fluke is found in mostly tropical and subtropical regions, including Australia, Asia, Africa, Eastern Europe, and Russia. Adult *Paramphistomum cervi* live in the rumens of ruminants (goats, sheep, cattle, and buffaloes), they live in the rumen and cause paramphistomiasis or amphistomiasis.

Adult Morphology: Rumen flukes are small, not longer than 15 mm and 5 cm wide. They have a grayish to reddish color. Unlike many fluke species, their body is not flattened but ventrally concave pear-shaped, with the head at the narrowest anterior end. They have two suckers, an oral and a ventral one, the ventral sucker is much larger and close to the posterior end, tests are lobed and located anterior to the ovary.

Eggs: operculated (130x80 micrometers), very similar to those of *Fasciola hepatica* but slightly lighter, they are unembryonated when released.



Life cycle: adult flukes in the intestine lay eggs that are shed outside with the feces. About 2 weeks later miracidia hatch out of the eggs. They swim in the water until they find a suitable snail. They penetrate into the snail and continue development to sporocysts and mother rediae, which multiply asexually and produce daughter rediae. Each redia produces several cercariae. Cercariae swim around and attach to the vegetation where they encyst and become metacercariae, encysted metacercariae do not survive in dryness, but can survive and remain infective for up to 1 year in a humid and temperate environment. Livestock ingests metacercariae while grazing in contaminated pastures. Once in the small intestine the young flukes leave the cysts, attach to the intestinal mucosa and continue development. They feed on the tissues of the gut wall. Later on, they detach from the gut's wall and migrate to the rumen, where they complete development to adult flukes.



Pathogenicity: Paramphistomiasis causes enteritis and anaemia in livestock mammals and result in economic losses. Adults attach to the villi in the rumens of the hosts and sap nutrients from the intestine. Pathological symptoms are produced by immature flukes, when the young flukes start to gather in the intestine, there is a watery and fetid diarrhea which is often associated with high mortality (even up to 80-90%) in ruminants, they attack the duodenal mucosa to induce acute enteritis. Surprisingly, the adult flukes are regarded as commensals and non-pathogenic.

Diagnosis and treatment: Symptoms are usually visible on the behavior of the host. Infected sheep and cattle become severely anorexic or digest food inefficiently. Continuous diarrhea is an obvious indication of heavy infection in the digestive system, the fluid faeces are examined to identify immature flukes. Treatments with reported success are resorantel, oxclozanide, clorsulon, ivermectin and the combination of bithional and levamisole.

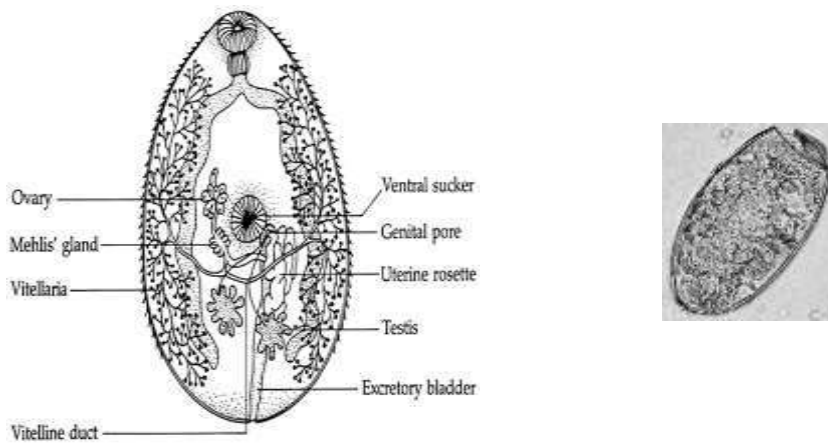
Third: Lung flukes

Paragonimus westermani, Oriental lung fluke- Kerbert- 1878.

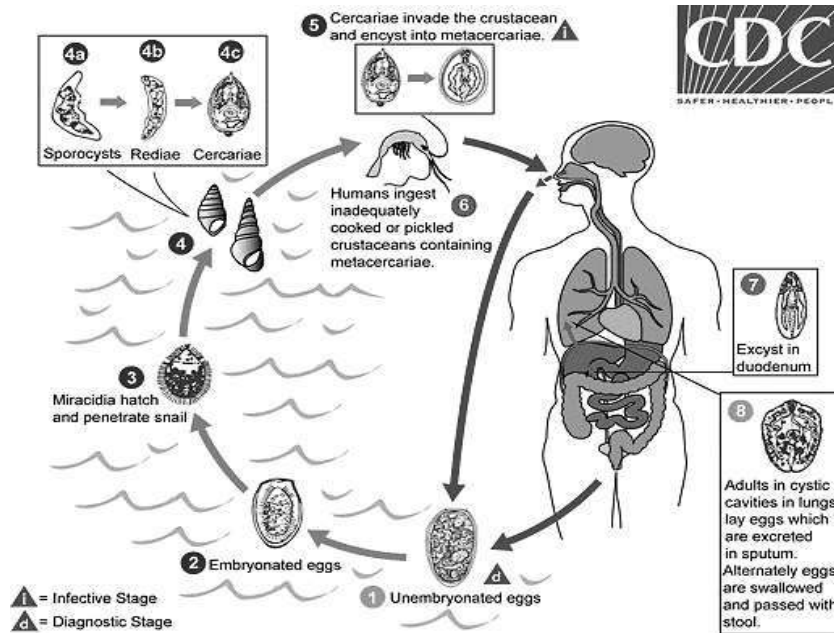
Disease: Paragonimiasis, pulmonary distomiasis.

Geographic distribution: Asia, Africa, South and North America, the most endemic regions are central China, Korea, Japan and Taiwan. Adult worms live in the lung of human.

Morphology: color reddish-brown, 7.5-12 mm length, 4-6 mm width and 3.5-5 mm thickness. The tegument bears scales like spines. Oral sucker and ventral sucker are sub equal in diameter. The two ceca extended in a zigzag manner. Two irregular testes, ovary is lobed and lies to the right or the left midline. The genital pore is posterior to the ventral sucker. Eggs are released with sputum of infected person and they are operculated and unembryonated.



Life cycle: The undeveloped ova are passed in the sputum or feces, they hatch in the water. The ciliated miracidium enters a suitable species of snail (*Thiara*) and develops successively into sporocyst, mother rediae, daughter rediae and cercariae. The cercariae emerge from snail at the night; these cercariae are minute with delicate knob-like tail. Non swimming cercariae are transported by water current and invade the viscera and muscles of fresh water crabs or crayfish and become encysted in their soft tissues. When cysts are ingested by the definitive host, young worm's excyst, migrate through the intestinal wall to peritoneal cavity, burrow through the diaphragm, enter the lungs, and finally settle down, usually in pairs, near bronchioles where they develop into adult worms.



Symptoms and pathology:

Acute phase: it occurs during invasion and migration of worms from intestine to lungs and marked by diarrhea, abdominal pain, fever, cough, urticaria, hepatosplenomegaly, pulmonary abnormalities, and eosinophilia.

Chronic phase: pulmonary manifestations include cough, expectoration of discolored sputum, hemoptysis, and chest radiographic abnormalities. Extrapulmonary locations of the adult worms result in more severe manifestations, especially when the brain is involved.

Diagnosis: Eggs in sputum or sometimes in feces.

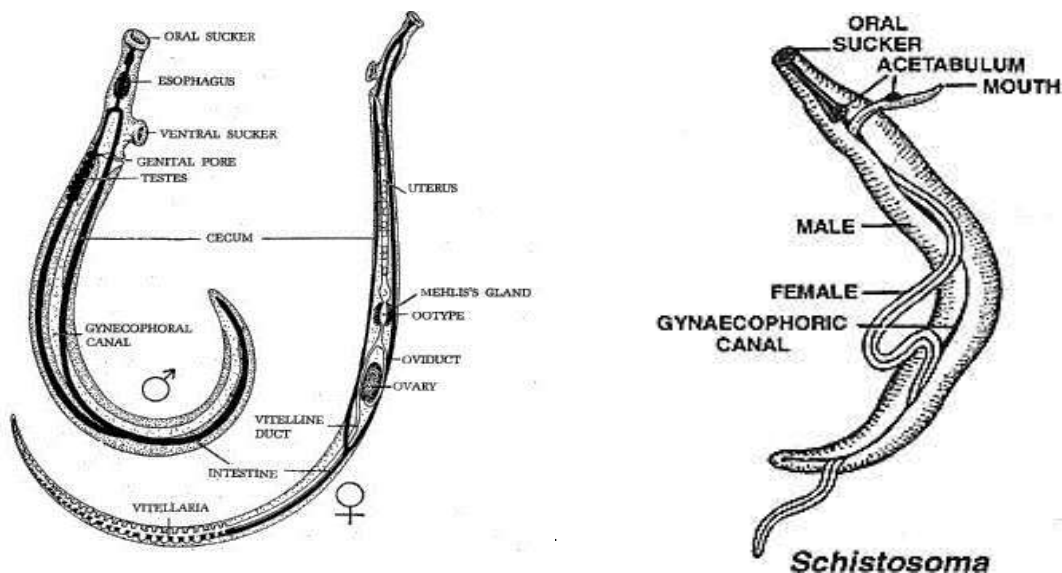
Treatment: Bithionol or Praziquantel.

Forth: Blood flukes

Blood flukes, the most important trematodes of man, they are different from other members of the digenea in that the sex are separated, the term *Schistosoma* means "split body" and refers to the fact that the males have a ventral groove called a gynecophoric canal, this canal extending the entire length of the body from the ventral sucker, in which the slender female is held during copulation.

Morphology:

- 1- The integument is smooth or tuberculate, depending on the species.
- 2- The oral and ventral suckers are located near the anterior end.
- 3- The intestine anterior to the ventral sucker divides into two ceca, which reunite in the posterior end, intestine contains ingested RBCs.
- 4- The male reproductive organs comprise (4-8) testes, situated dorsal and posterior to the ventral sucker.
- 5- The female have a cylindrical shape with pointed ends, they often lie in the gynecophoric canal of the male with terminal end free.
- 6- The female reproductive organs consist of an elongate ovary the position of which varies in the different species.
- 7- The uterus extends forward from the ootype, where fertilization takes place to the genital pore just behind the ventral sucker. The length of uterus and the number of ova are important features of species differentiation.



There are three main species of the genus *Schistosoma*, which produce serious human schistosomiasis; these three species are similar to each other with some differences in the morphological details and pathogenesis:

a) *Schistosoma haematobium*

Disease: Vesical schistosomiasis, bilharziasis.

Geographic distribution: Africa, Middle East.

b) *Schistosoma mansoni*

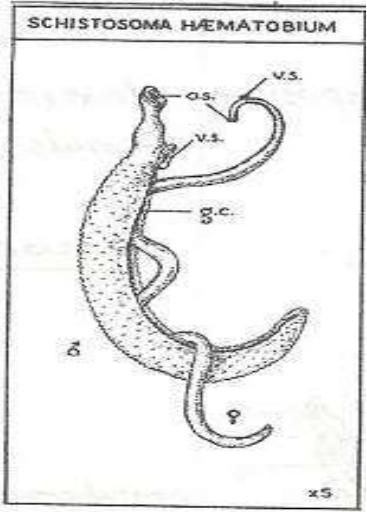
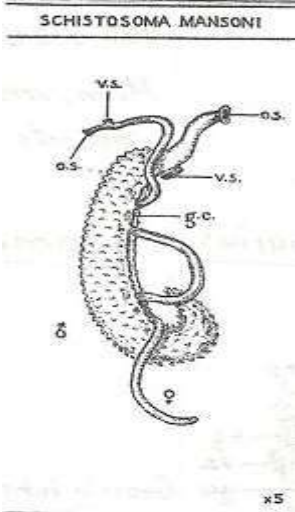
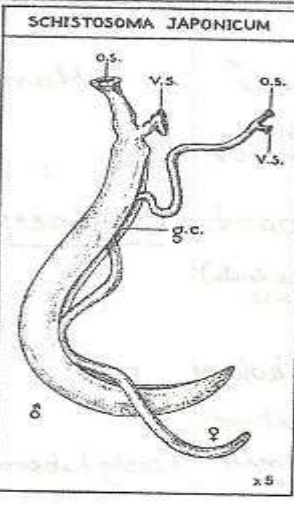
Disease: Intestinal schistosomiasis.







Geographic distribution: Africa, Middle East, South America, and a number of Caribbean islands.

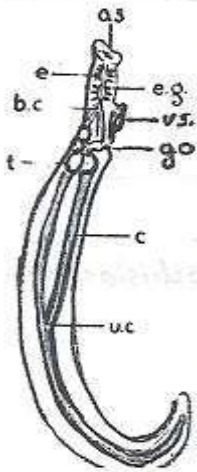
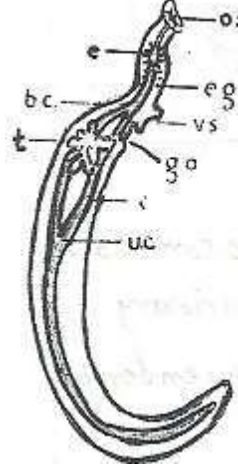
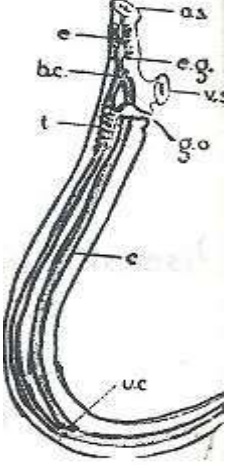
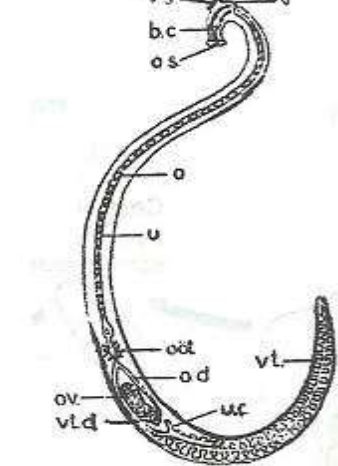
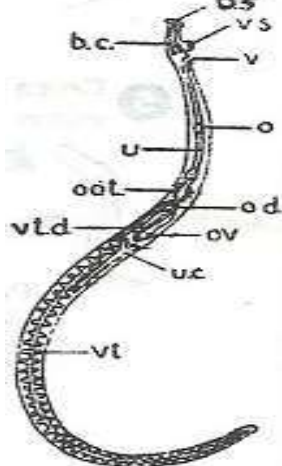
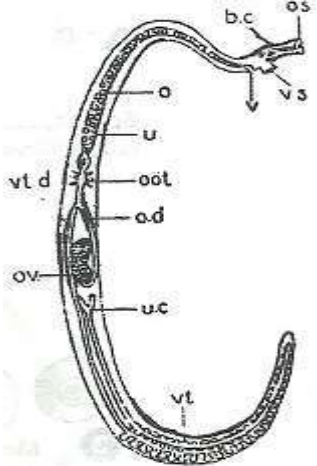
c) *Schistosoma japonicum*

Disease: Oriental intestinal schistosomiasis.

Geographic distribution: Japan, China, Taiwan, Philippines and Indonesia.

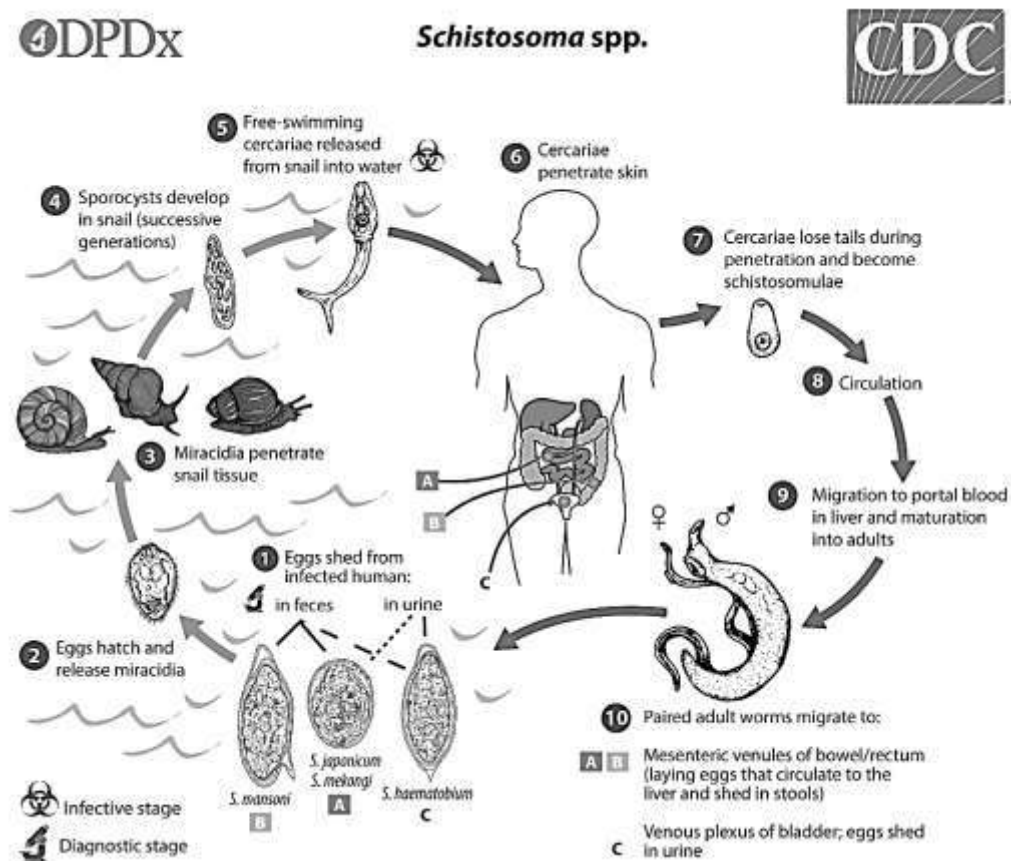
<p><i>Schistosoma</i> Spp.</p>	<p>SCHISTOSOMA HAEMATOBIMUM</p> 	<p>SCHISTOSOMA MANSONI</p> 	<p>SCHISTOSOMA JAPONICUM</p> 
<p>Disease</p>	<p>Schistosomal bilharzia</p>	<p>Intestinal schistosomiasis</p>	<p>Oriental intestinal schistosomiasis, Katayama disease, Hankow fever.</p>

Geographic distribution	Africa, western Asia, southern Europe. Endemic hematuria.	Africa, South America, west Indies.	China, Japan, Formosa, Philippines.
Habitat of adult in human	Vesical and pelvic venous plexuses, less frequently mesenteric and portal system.	Mesenteric venules of lower intestine (inferior mesenteric venules) less portal system, vesical plexus.	Radicals of superior mesenteric veins.
Ovum	Bladder and genitalia, less frequently intestine. Large with terminal spine in urine more than feces 143x60μ. 	Intestine and mesenteric lymph nodes, less frequently bladder. Larger with later spine in feces more than urine 155x66μ. 	Intestine and mesenteric lymph nodes Small with short spine 89x67μ in feces. 
Natural hosts (final host)	Human	Human, monkeys, oposums, rodents.	Human, domesticated animals and wild rodents.
Gastropods intermediate host	<i>Bulinus, Planorbium</i> 	<i>Biomphalaria</i> , 	<i>Oncomelania</i> 

Morphology of adult male			
Tegument	Finely tuberculate	Grossly tuberculate	Non-tuberculate
Ceca	Join at the 2 nd half pf body	Join at 1 st half of the body	Join at the end of the body
Testes	4-5 large	7(3-13) small	7(6-8) medium
Size	1.3x0.09 cm	1.0x0.11 cm	1.5x0.05 cm
Adult female			
Ovary location	Posterior half of body.	Anterior half of body.	Middle of body.
Uterus	Big with 20-30 ova long.	Short with 1-4 ova.	Long with 50-100 ova.
Size	2.2x0.025 cm	1.4x0.016 cm	1.9x0.03 cm

Life Cycle:

Schistosoma eggs are eliminated with feces or urine, depending on species. Under appropriate conditions the eggs hatch and release miracidia, which swim and penetrate specific snail intermediate hosts. The stages in the snail include two generations of sporocysts and the production of forked-tail cercariae (infective stage). Upon release from the snail, the infective cercariae swim, penetrate the skin of the human host, and shed their forked tail, also called schistosomulae. The schistosomulae migrate via venous circulation to lungs, then to the heart, and then develop in the liver, exiting the liver via the portal vein system and mature, then move its final position depending on the species. Male and female adult worms copulate, female starts producing eggs, which are shedding through urine or stool. *S. haematobium*, takes 10-12 weeks for maturation; *S. mansoni* 7-8 takes weeks; *S. japonicum* takes 5-6 weeks.



Pathology and clinical features:

S. haematobium: Hematuria (blood in urine), bladder loses its elasticity, may secondarily cause nephritis and kidney failure.

S. mansoni: Pathology depends upon degree of initial infection and on prolonged period of reinfection. In liver, worm may provoke hypersensitivity and may be hepatitis. Main damage comes from inflammation, necrosis, and connective tissue encapsulation.

Symptoms include explosive onset: Fever, chills, abdominal pain, dysentery, hepatic problems, pipestem fibrosis and cirrhosis. Eggs may be lodged in intestinal mucosa and cause pseudoabscesses main cause of all problems, with both mechanical damage. Rectal cancer may occurs in chronic infection.

S. japonicum: similar to *S. mansoni*, often eggs end up in lungs, brain and heart.

Diagnosis:

S. haematobium: Eggs in urine (99%), only 1% in feces, large eggs with posterior "terminal" spine.

S. mansoni: Eggs in feces and urine, large eggs with lateral spine.

S. japonicum: 100% of eggs in feces, eggs are small, round and much smaller spine.

Treatment:

Praziquantel is effective for the treatment of human schistosomiasis caused by any species.

Phylum Platyhelminthes, Class: Cestoda (tapeworms)

Cestodes or tapeworms are the most specialized of the Platyhelminthes parasites. All cestodes have at least one, and sometimes more than one intermediate host (invertebrates) as well as definitive host (vertebrates). In some cases, both hosts are vertebrates, as in the common Beef Tapeworm *Taenia saginata*, and in a few species there may be only a single host. Tapeworms infect human and animals causing mild to serious infections. There are more than 1,000 species of tapeworms.

The mature Cestode always live in the hosts intestines where it can obtain all its food. Cestodes have evolved to have no digestive system of their own, they simply absorb nutrients from their hosts guts. To aid this process the entire surface of their body is covered with microscopic projections, which greatly increase the surface area available for the absorption of nutrients. They have no need to travel and therefore have no locomotor organs (cilia). Their excretory and nervous systems are similar to other. Typical adult tapeworm consists of a knoblike head, or scolex, equipped with hooks for attaching to the intestinal wall of the final host, a neck region (germinative), and a series of flat, rectangular body segments (strobila), generated by the neck. The chain of proglottids ranges from a few number to more than 1000 segments.

1- Subclass: Cestodaria

The subclass Cestodaria consists of monozoic (unsegmented) tapeworms, with a single set of reproductive organs. No scolex is present and the shelled embryo contains ten hooks. All are parasites of fish.

2- Subclass: Eucestoda

The true tapeworms are usually polyzoic (segmented), comprised of a scolex which functions as a holdfast and a strobila that is divided into many proglottids. The scolex is the anterior end of the tapeworm and can be equipped with a variety of attachment structures. The scolex may bear suckers, grooves, hooks, spines or any 2 combination of any. In the strobila, each proglottid potentially contains one or more sets of both male and female reproductive organs, making the tapeworms hermaphroditic. Proglottids are

added on in the “neck” region (by a process called strobilation) between the scolex and strobila, and mature as they move down the body. The male system develops first and anterior proglottids will often contain only male organs. Older proglottids will contain both reproductive systems.

Ova may be released through the uterine pore or the entire gravid proglottid may break off (apolysis) releasing eggs as it breaks up. True tapeworms usually produce a hexacanth embryo (6-hooked). This subclass has 2 orders of tapeworms: Pseudophyllidae and Cyclophyllidea.

a- Order: Pseudophyllidae

Adult pseudophyllidean tapeworms are parasites of all classes of vertebrates, but fish are their primary host. The life cycle involves a procercoid (larval stage found in copepods) and plerocercoid larval stage (found in fish). Tapeworms in this order are characterized by:

- 1- A bothriate scolex: possessing a dorsal and a ventral groove or bothrium.
- 2- A neck may be present or absent.
- 3- Testes and vitellaria are follicular and scattered throughout the proglottid.
- 4- The ovary is bilobed and posterior.
- 5- Genital pores are usually ventral and may be lateral or dorsal in some groups.
- 6- A uterine pore is present on the dorsal or ventral surface.
- 7- The eggs are usually operculate and contain a ciliated embryo, the coracidium.

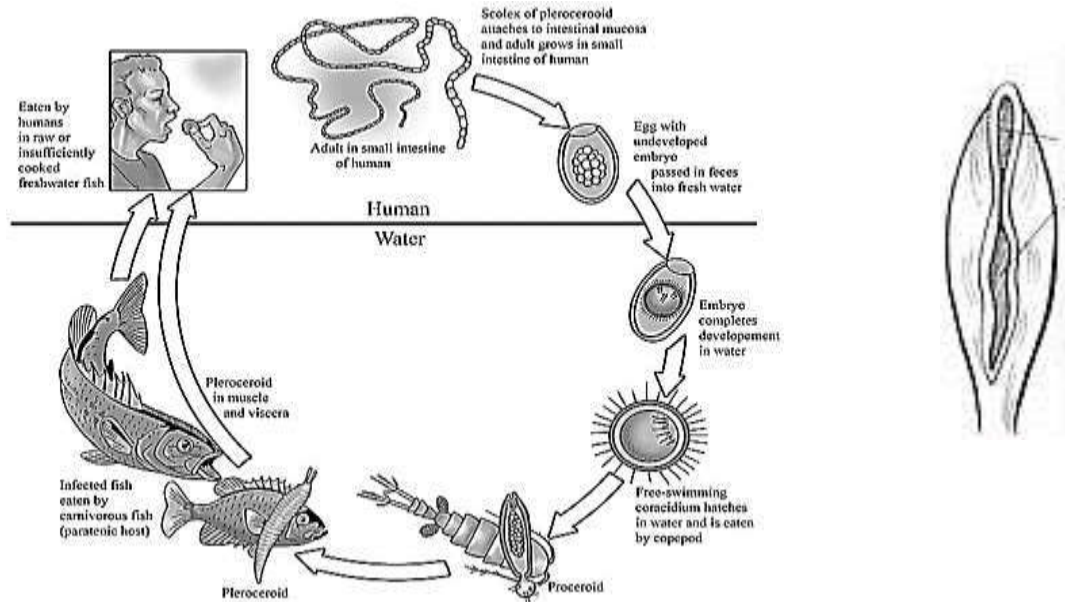
Examples of Cestoda worms

Diphyllobothrium latum: Commonly called the broad fish tapeworm and causes diphyllobothriasis. This cestode is common in fish-eating carnivores in northern Europe, Russia, the Arctic, and the Great Lakes areas of North America. There appears to be little host specificity for adults have been recovered from the intestine of many canines, felines, pinnipeds, bears, and humans. In humans *D. latum* can be a serious pathogen, causing a pernicious anemia. This is due to the worm absorbing large amounts of vitamin B₁₂.

Morphology: The adult worm reaches a length of 10m or more and may contain up to 3000 proglottids. The scolex of *D. latum* is elongate, spoon-shaped, and has two long sucking grooves, one on the dorsal and the other on the ventral surface. The mature and gravid proglottids are wider than long, with the main reproductive structures (mainly the uterus) located in the center of the gravid proglottid. Both eggs and proglottids may be found in the stool, all proglottids are wider than they long and the genital pore open mid-ventrally.

Eggs: about 40 x 60 µm in size. Broadly oval and operculated, there is a small nub on the abuperculated end, unembryonated when released. Ova are shed up to a million in one days.

Life cycle: After developing for 2 weeks in fresh water, the eggs hatch and the ciliated, coracidium larvae are ingested by the first intermediate host, the copepod (crustacean). Fish then ingest the copepods, containing the second larval stage (proceroid), the 2nd intermediate host fish contains many plerocercoid larvae which initiate the infection with the adult worm when ingested by human.



Pathogenicity: Most individuals infected with a fish tapeworm are asymptomatic. However, digestive disturbances including abdominal pain and cramps accompanied by weight loss may occur, but healthy individuals may experience few symptoms. Anemia, or pernicious anemia in heavy infection, follows due to a vitamin B₁₂ deficiency, due to the presence of the parasites infecting the intestine. Diagnosis by ova in stool.

Sparganosis: Helminthic disease caused by *Spirometra mansoni* (or *Dipyllobothrium mansoni*) which infects cats and dogs. It is caused by the plerocercoid of this worm when reaching the human, accidentally (not the final host) so the human serves as 2nd or paratenic intermediate host. Spargana (plerocercoid) can migrate to many parts of the body, including subcutaneous tissue, breast, orbit, urinary tract, pleural cavity, lung, abdominal viscera and brain.

b- Cyclophyllidea: Members of this order are common parasites in the intestines of amphibians, reptiles, birds and mammals. They are characterized by:

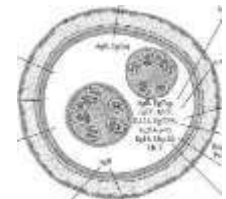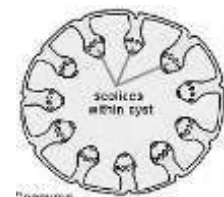
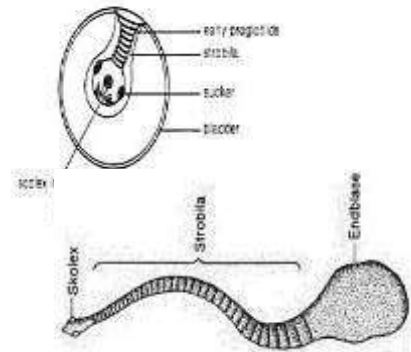
- 1- The scolex usually contains four cup-shaped suckers.
- 2- The rostellum usually present or absent, and may or may not be armed.
- 3- Uterine pore is absent so gravid proglottids developed.
- 4- Genital pore is lateral to the proglottid.

- 5- Vitelline gland is single, compact, and usually posterior to the ovary.
- 6- Proglottids are often wider than long.

Gravid segments generally leave the host's body individually, but may also be released in groups. Non-operculated eggs escape by rupture or disintegration of gravid proglottids and develop into some form of bladderworm in an invertebrate or vertebrate intermediate host. Infective eggs contain an oncosphere larva that bears 6 hooks.

They have a variety of intermediate host types, both invertebrate and vertebrate. Depending on the cestode species, **the larval cestodiasis stage in the vertebrate intermediate host** may be as cysticercus, strobilocercus, coenurus (multiceps), or hydatid cyst.

- **Cysticercus** has a bladder-like form with an invaginated scolex located at one end.
- **Strobilocercus** is similar to the adult worm, in which a scolex is visible, but has a terminal bladder end rather than proglottids.
- **Coenurus** is similar to the cysticercus but bears multiple scoleces.
- **Hydatid cyst**, brood pouches develop within the bladder and gives rise to multiple scolices (up to 20) and each hydatid cyst may contain thousands of scolices.



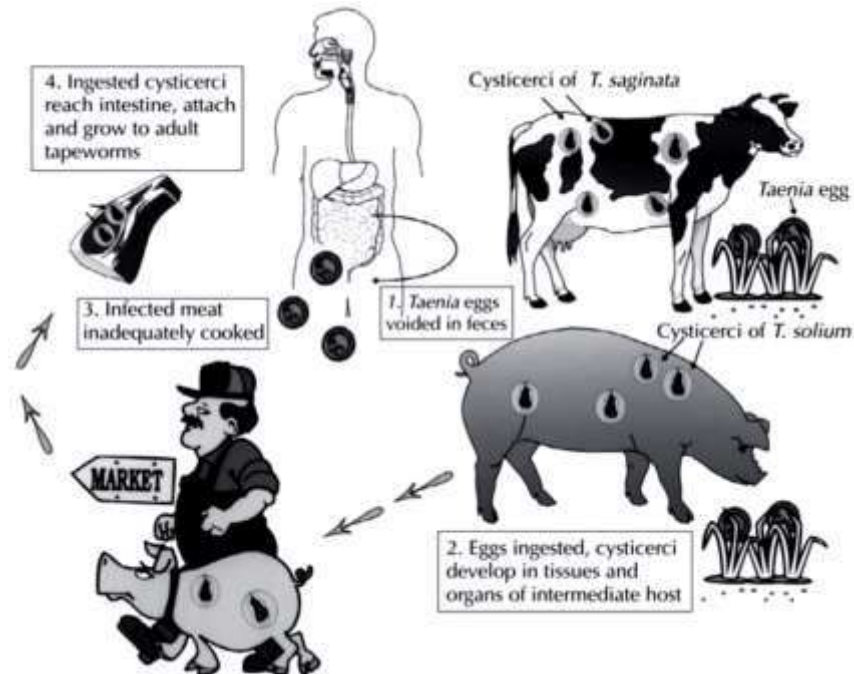
The Larvae in invertebrate intermediate hosts (usually arthropods) are cysticercoids; these have no bladder but a simple invaginated scolex. The scolex has 4 prominent suckers and a terminal rostellum, which may or may not be armed with hooks.

Genus *Taenia* spp.

There are several species of *Taenia* that humans are likely to encounter. These include two species for which humans serve as the definitive host: *Taenia saginata*, the beef tapeworm; and *T. solium*, the pork tapeworm. Several species of *Taenia* also infect dogs and cats (e.g., *T. pisiformis*), and humans are likely to encounter these when they note the presence of these tapeworms' proglottids in their pets' feces.

All species of *Taenia* have similar life cycles. The adult tapeworm lives in the definitive host's small intestine. Proglottids, which contain eggs, break off the posterior end of the tapeworm, and these proglottids are either passed intact in the host's feces or they dissolve in the host's intestine and eggs are passed in the feces. When a suitable intermediate host ingests the eggs, the oncosphere larva is released and, with the aid of the embryonic hooks, penetrates the intestinal wall and enters the bloodstream. Upon reaching the liver, the oncosphere begins to develop into a cysticercus. Bladder-worms break out of the liver and attach to the mesenteries throughout the abdominal cavity. The definitive host is infected when it eats an intermediate host infected with cysticerci. Upon ingestion, the scolex evaginates, attaches to the intestinal lining, the bladder disintegrates, and the strobila is formed by the budding of the neck region.

As adults in the definitive host's small intestine, tapeworms rarely cause problems; in exceptional cases, the tapeworms might physically block the intestinal tract, due to their large size, or proglottids might become lodged in the appendix and result in appendicitis. The proglottids of *Taenia* are large and muscular. Occasionally single proglottids or long chains of proglottids might crawl out of the anus of an infected human. Larval stage of *T. solium* is *Cysticercus cellulosae*, which is the infective stage to humans, *T. saginata* infective stage to humans is *Cysticercus bovis*.



Cysticercosis: It is a systemic infection caused by dissemination of the larval form of the pork tapeworm, *Taenia solium*. A high prevalence has been reported from the developing countries because of the co-existence of poor sanitary conditions and domestic pig raising without proper veterinary control or surveillance systems. It occurs mainly in pork eating nations due to consumption of undercooked pork. Humans are the definitive hosts and carry the infective *Cysticercus* and intestinal adult tapeworm. Human cysticercosis occurs when **eggs** are ingested via faecal-oral transmission from a tapeworm host. The human then becomes an accidental intermediate or paratenic host, with development of cysticercosis within organs. Cysticercosis can affect various organs, such as brain, spinal cord, muscles, orbit, subcutaneous tissues and heart. The clinical manifestation of the patient varies depending upon the site of larval encystment, number of cyst and the extent of associated inflammatory responses. CT scan and MRI are used for diagnosis.

Taenia multiceps: tapeworm of the small intestine of dogs and other canines, has a larva called coenurus, which develops in the brain of sheep, causing the dizzy, and exceptionally in the human brain then determining the coenurus.

Cerebral coenurosis: it is a parasitic infection caused by larvae of the tapeworm *T. multiceps*; it develops in the intermediate host and rarely infect

humans. Cerebral coenurosis cysts cause ventricular obstruction and increased intracranial pressure. On CT scan, viable cysts appear as lesions.

Treatment: Praziquantel opens membrane calcium channels causing paralysis of the worm, aiding the body in expelling the parasite through peristalsis. Niclosamide, used to treat many different kinds of infections with trematodes and adult tapeworms, is quite effective.

Echinococcosis:

Echinococcosis is a zoonotic disease caused by *Echinococcus* spp. tapeworms. The definitive hosts, which include dogs, other canids, hyenas and cats, carry the adult tapeworms subclinically. Dogs are particularly important in zoonotic transmission due to their close relationships with humans. Intermediate hosts are initially asymptomatic; however, the growth of the larvae, which form cysts in vital organs such as the liver and lungs, can lead to illness and death. Echinococcosis is a major public health problem in some countries, approximately 2-3 million human cases are thought to occur worldwide.

Cystic echinococcosis (Hydatid cyst), the most common form of the disease in people and domesticated animals, is caused by *Echinococcus granulosus*. Because the larvae of this organism usually develop as discrete single cysts, it is the least severe and most treatable form. Nevertheless, large or multiple cysts may cause irreversible damage to organs, and the rupture or puncture of the cyst can seed multiple organs with larvae or cause anaphylactic reactions. Humans typically become symptomatic many years after infection. Cystic echinococcosis causes economic losses from the condemnation of internal organs at meat inspection. In some cases, it may also result in decreased meat and milk production or decreased value of the fleece due to debilitation.

Alveolar echinococcosis, caused by *E. multilocularis*, is less common than cystic echinococcosis, but it is very serious and more difficult to treat. The larvae of this organism grow as multiple, budding cysts, which can infiltrate entire organs and disseminate to distant sites including the brain. As well as affecting people, alveolar echinococcosis is reported to cause serious disease in animal intermediate hosts including dogs. The occurrence of this organism

in a wildlife cycle between foxes and small mammals makes it difficult to prevent. Polycystic echinococcosis, which is usually caused by *Echinococcus vogeli* in humans, is similar to alveolar echinococcosis in the growth of the larvae and its presence in wildlife hosts.

Echinococcus granulosus or hydatid worm:

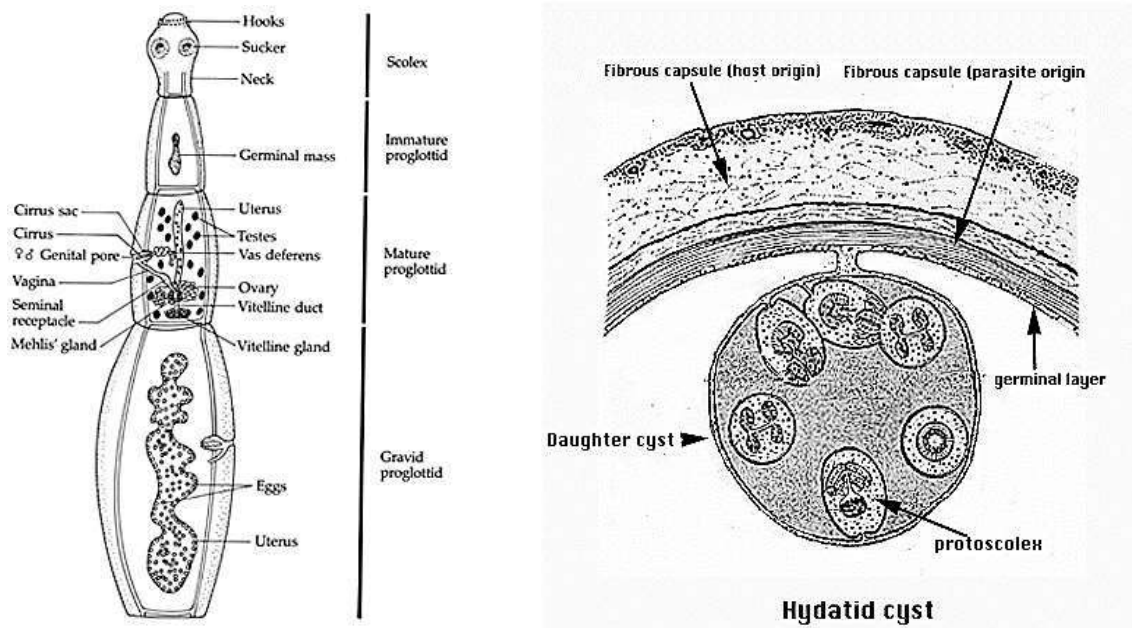
Morphology: Tape-worms form three different developmental stages: eggs; larvae; and adults. Adult *E. granulosus* worms are small (2-6 mm long) and have a scolex with only three attached segments. The scolex has four lateral suckers and the rostellum is non-retractable and armed with a double crown of 28-50 recurved hooks. The anterior segment is immature, the middle segment is mature with functional testes and ovaries, and the posterior segment is gravid with the uterus filled with eggs. The eggs are typical for most taeniid species and are small and round (30-43µm in diameter), thick-shelled and contain a hexacanth (6-hooked) embryo (oncosphere). The encysted larval (metacestode) stage is known as a bladder-worm or hydatid, and it produces multiple infective stages (protoscoleces, apparent as invaginated scolices already containing suckers and hooks) either directly from the germinal layer of the cyst wall, or by forming brood sacs (hydatid sand) by endogenous (internal) or exogenous (external) budding of the germinal layer.

Types of hydatid cysts:

1- *E. granulosus* forms fluid-filled unilocular cysts with endogenous budding of brood capsules, fluid-filled sphere with germinal membrane proliferating endogenously to form brood capsules.

2- *E. vogeli* forms fluid-filled polycystic cysts with exogenous budding, fluid-filled with germinal membrane budding exogenously to form new cysts and endogenously to form septae.

3- *E. multilocularis* forms fluid-free multilocular or alveolar cysts with exogenous budding, germinal membrane budding exogenously to form multiple cysts with no free fluid.

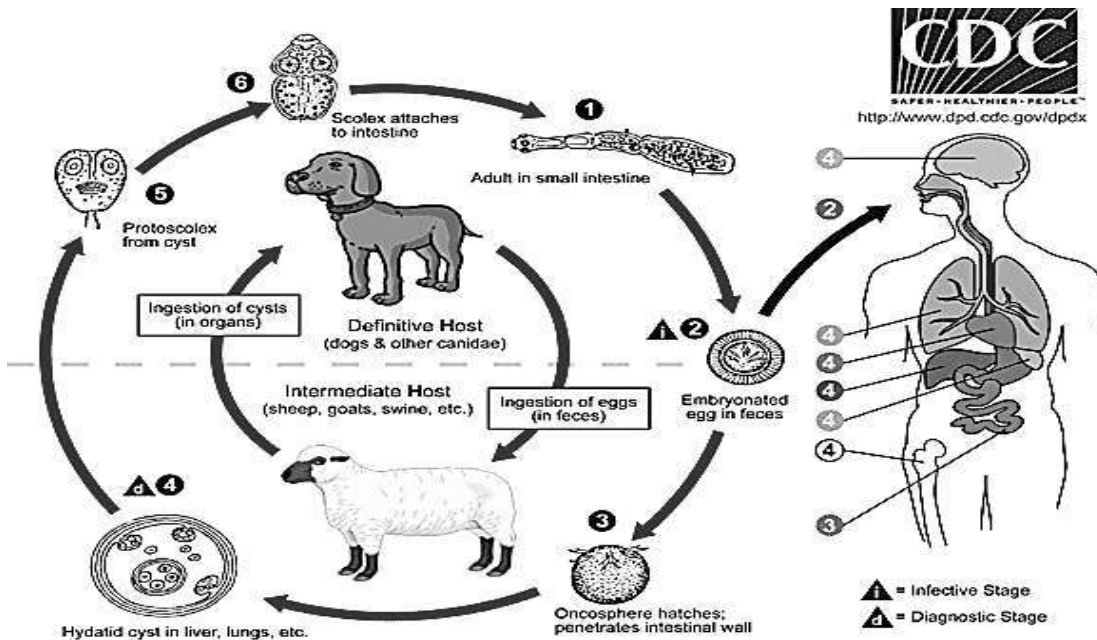


Life Cycle: The definitive hosts for *E. granulosus* (canids, felids, and hyaenids) become infected when they ingest cysts (metacestodes) in the tissues of the intermediate hosts. Feeding the viscera of intermediate hosts to dogs perpetuates cycles in domesticated animals. The cysts develop into tapeworms, which mature in the host's small intestine. Gravid proglottids or eggs are shed in the feces, and are immediately infective. *Echinococcus* eggs have a sticky coat that will adhere to an animal's fur and other objects. Insects such as flies and beetles, or birds, can also act as mechanical vectors.

Under ideal conditions, *E. granulosus* eggs remain viable for several weeks or months in pastures or gardens, and on fomites. The eggs survive for only short periods of time if they are exposed to direct sunlight and dry conditions. The intermediate hosts include a large number of domesticated and wild animals, particularly herbivores. Humans can also be infected. If an intermediate host ingests the eggs, the larvae are released, penetrate the intestinal wall, and are carried in blood or lymph to the target organs.

Parasites can develop into cysts in many different organs, but they are found most often in the liver and, less frequently, the lungs. The rate of development varies with the intermediate host and species of parasite, but the cysts usually

grow slowly. Their diameter generally increases from less than 1 cm to 5 cm each year. Some cysts may persist unchanged for years. Most *E. granulosus* cysts are 1-7 cm in diameter when they are discovered, but some may eventually reach 20 cm. Each fluid-filled cyst is surrounded by a fibrous wall from the host and contains two walls derived from the parasite: an outer laminated membrane and an inner membrane called the germinal layer. Brood capsules develop from the germinal membrane. Each brood capsule contains one to several invaginated heads (protoscolices) that can develop into adult tapeworms if they are ingested by the definitive host. Capsules and protoscolices either float freely in the hydatid fluid or adhere to the wall with a peduncle; the capsules and protoscolices that float freely are known as “hydatid sand.” If a cyst ruptures, the hydatid sand can develop into new cysts. Some cysts are sterile; they either never produce brood capsules, or they become sterile after bacterial infection or calcification.



Pathogenesis: The adult stages are considered benign and do not cause disease in dogs, as the worms do not invade or feed on host tissues. Encysted larval stages generally do not cause clinical disease in domestic livestock as they are often confined to visceral tissues.

The symptoms of echinococcosis depend on the size, number and the location of the metacestodes. Until the cysts become large enough to damage adjacent tissues and organs, they are usually asymptomatic. The clinical signs are those of a mass lesion. Significant pathological changes occur in humans, or other intermediate hosts, when the slowly growing cysts put pressure on surrounding tissues and produce chronic space-occupying lesions. Cysts may grow around 1 mm per month and can become extremely large, up to 30 cm in diameter with liters of fluid containing thousands of protoscoleces. Organ enlargement may be accompanied by a variety of clinical signs depending on the size and location of the cysts. Compression of liver may result in jaundice, portal hypertension and abdominal distention. Cysts in the lung may cause haemoptysis (coughing up blood), dyspnoea (difficulty breathing) and chest pain. Cysts in the brain or spinal cord can provoke acute inflammatory responses and numerous neurological sequelae, including epilepsy and blindness. Cyst rupture has been associated with acute clinical signs (such as peritonitis and pneumothorax), and the sudden release of hydatid fluid may cause severe allergic reactions (such as asthma and anaphylactic shock). Protoscoleces released from ruptured cysts can regress and form new hydatid cysts throughout the body.

Differential diagnosis: Infections in dogs may be diagnosed by the detection of eggs, and occasionally worms, in faecal samples. Infections in intermediate hosts are diagnosed well after the larvae have encysted. Clinical symptoms of a slow-growing tumour accompanied by eosinophilia. Cysts can be visualized by computerized axial tomography (CAT) scans, X-rays or ultrasound.

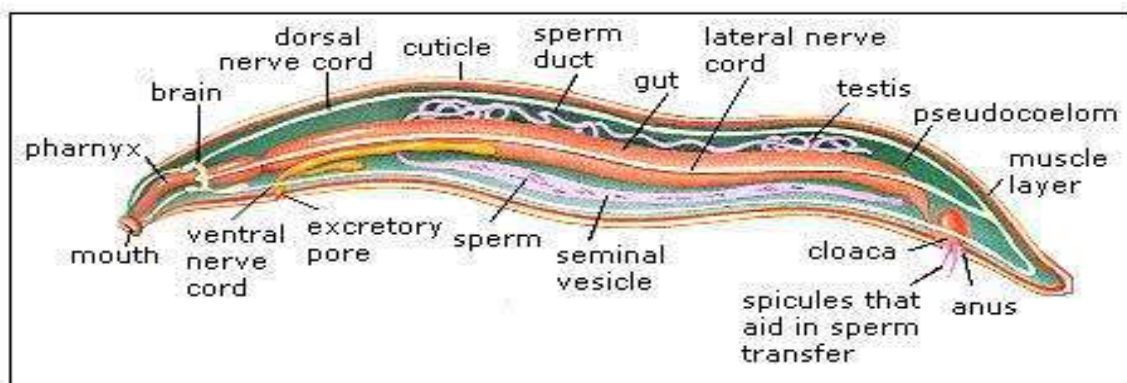
Phylum Aschelminthes

Nematode species are very difficult to distinguish; over 28,000 have been described, of which over 16,000 are parasitic. It has been estimated that the total number of nematode species might be approximately 1,000,000.

Distinguishing Characters:

- (1) Body is vermiform, triploblastic with bilateral symmetry.
- (2) Body is unsegmented.
- (3) Digestive system complete. Anus is present.
- (4) **The coelom is not a true coelom. Hence the coelom of Aschelminthes is called a false coelom (Pseudo-coelom).** There is no mesodermal lining over the inner side of the body cavity.
- (5) Circulatory and respiratory organs absent.
- (6) Nervous system with cerebral ganglia and nerves.
- (7) Sexes are separate. Male usually is smaller than female.
- (8) Life cycle with or without larval stage.
- (9) Mostly parasitic, some are free living forms in the soil.
- (10) Body has well developed muscles. Longitudinal muscles are arranged in four distinct bundles.

Nematode



Anatomy

Nematodes are slender, worm-like animals, typically less than 2.5 millimeters long. The smallest nematodes are microscopic, while free-living species can reach as much as 5 centimeters and some parasitic species are larger. The body is often ornamented with ridges, rings, warts, bristles or other distinctive structures.

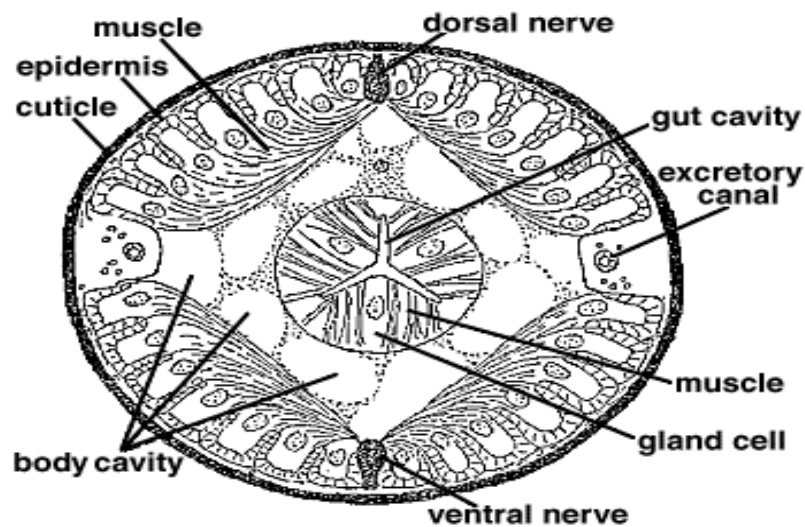
The head of a nematode is relatively distinctive. Whereas the rest of the body is bilaterally symmetrical, the head with sensory bristles. The mouth has either three or six lips, which often bear a series of teeth on their inner edge. An adhesive caudal gland is often found at the tip of the tail.

Tegument

1- The epidermis is either a syncytium or a single layer of cells, and is covered by a thick collagenous cuticle. The cuticle may have two or three distinct layers. Epidermis and **cuticle** both tough and flexible; the cuticle is periodically **shed** during the life of a nematode as it grows, usually **four times** before reaching the adult stage.

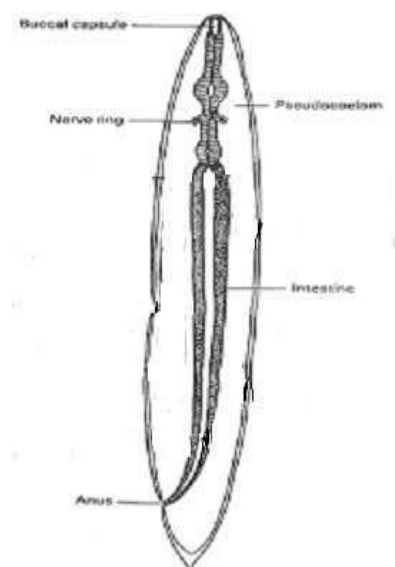
2- Underneath the epidermis lies a layer of muscle cells. Projections run from the inner surface of these cells towards the nerve cords; **this is a unique arrangement in the animal kingdom, in which nerve cells normally extend fibers into the muscles rather than *vice versa*.**

3- The muscle layer surrounds the body cavity, which is filled with a fluid that lacks any form of blood cells.



Digestive system

- The mouth often includes a sharp stylet which the animal can thrust into its prey.
- Sucking pharynx, also. Digestive glands are found in this region of the gut.
- No stomach, pharynx connecting directly to the intestine that forms the main length of the gut. This produces further enzymes, and also absorbs nutrients through its lining.
- The last portion of the intestine forming a rectum in front of the tip of the tail.



Excretory system

- Nitrogenous wastes is excreted in the form of ammonia through the body wall, and has no circulatory or respiratory organs.
- Most nematodes have an organ consisting of two parallel ducts connected by a single transverse duct. This transverse duct opens into a common canal that runs to the excretory pore.

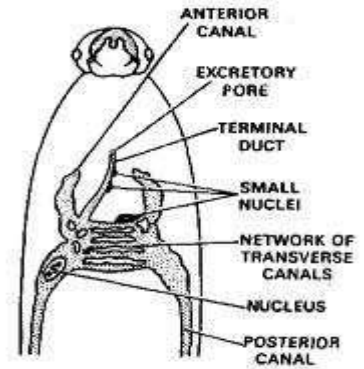


Fig. 15.10 Excretory system of *Ascaris* shown only in anterior part of body

Nervous system

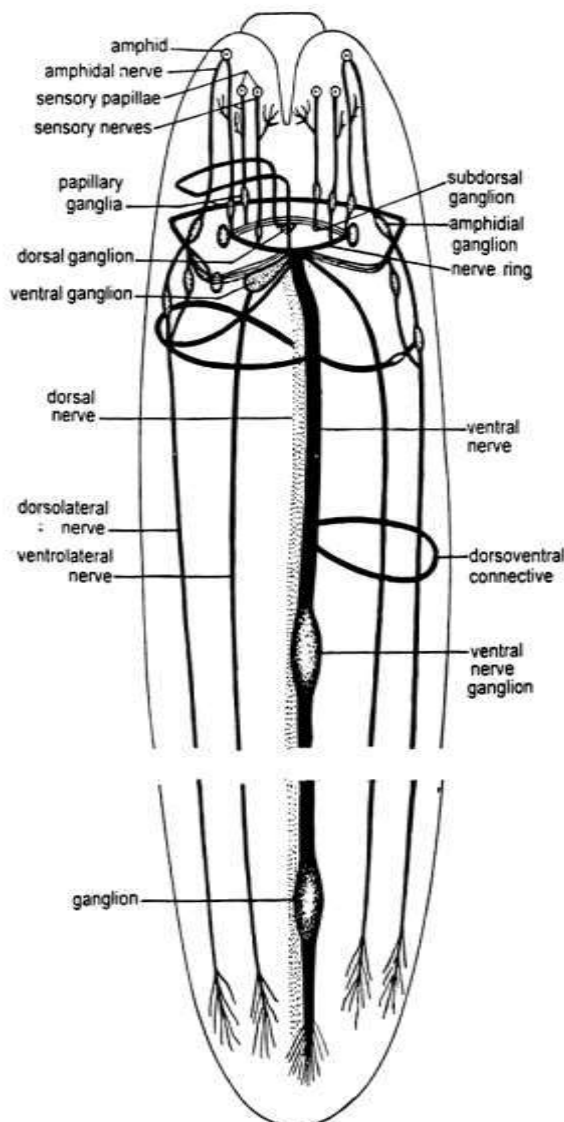


Fig. 23.5. *Ascaris lumbricoides*. Nervous system (diagrammatic—magnified)

Four nerves run the length of the body on the dorsal, ventral, and lateral surfaces. Each nerve lies within a cord of connective tissue lying beneath the cuticle and between the muscle cells. The ventral nerve is the largest. **The dorsal nerve is responsible for motor control, while the lateral nerves are sensory, and the ventral combines both functions.**

At the anterior end of the animal, the nerves branch from a dense circular nerve ring surrounding the pharynx, and serving as the brain. Smaller nerves run forward from the ring to supply the sensory organs of the head.

The body of nematodes is covered in numerous sensory bristles and papillae that together provide a sense of touch. Behind the sensory bristles on the head lie two small pits, or *amphids*. These are well supplied with nerve cells, and are probably chemoreception organs.

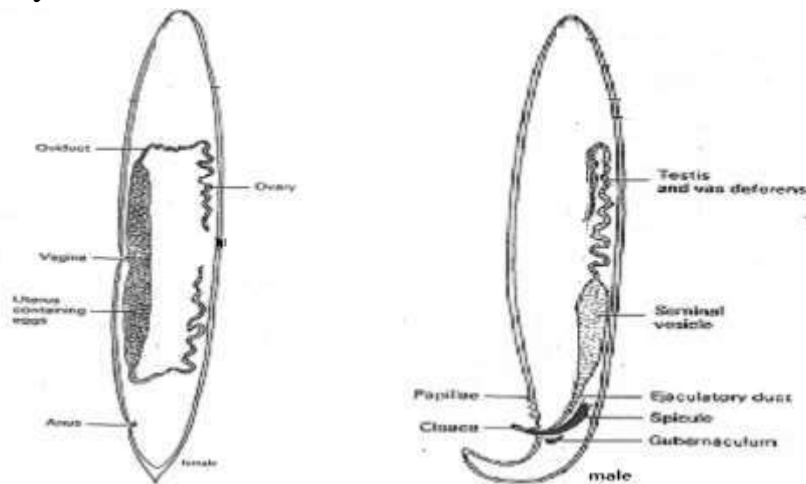
Unlike other animals, where the nerves branch out to the muscle cells, a nematode's muscle cells branch toward the nerves.

Reproduction

Most nematode species are dioeciously, with separate male and female individuals. Both sexes possess one or two tubular gonads.

In **males**, the sperm are produced at the end of the gonad, and migrate along its length as they mature. The testes each open into a relatively wide sperm duct and then into a glandular and muscular ejaculatory duct associated with the cloaca. During copulation, one or more chitinized spicules move out of the cloaca and are inserted into genital pore of the female.

In **females**, the ovaries each open into an oviduct and then a glandular uterus. The uteri both open into a common vagina, usually located in the middle of the ventral surface. Eggs may be embryonated or unembryonated when passed by the female, meaning that their fertilized eggs may not yet be developed. A few species are known to be **ovoviviparous**. The eggs are protected by an outer shell, secreted by the uterus.



First: Class Adenophorea or Aphasmidia characterized by:

- Amphids always post-labial.
- Phasmids are absent.
- Simple non-tubular excretory system when present.
- Both sexes with single gonad.
- Male with one spicule.
- Caudal alae are rare.
- Mostly free living and some parasitic.

ex. *Trichuris trichura*

Second: Class Secernentea are the main class of nematodes, characterized by:

- Amphids poorly developed.
- Phasmid present.
- An excretory system possessing lateral canals.
- Female reproductive system is double.
- Numerous caudal papillae.
- Males with two spicules.

Class Adenophorea or Aphasmidia

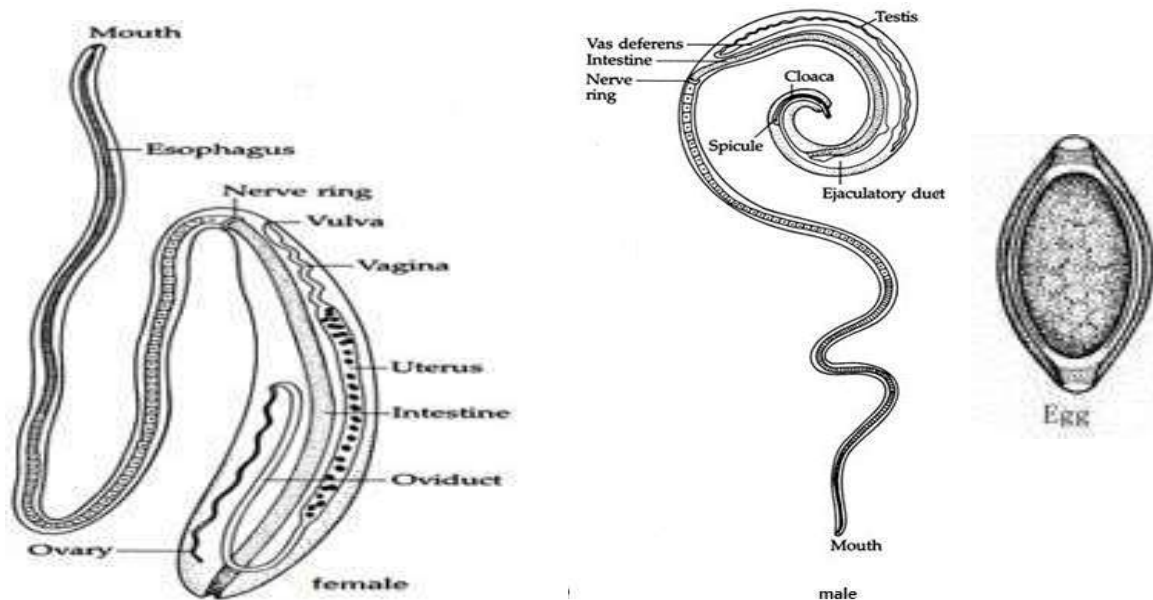
★ *Trichuris trichiura* (human whipworm)

Disease: Trichuriasis in cecum, appendix, colon and rectum.

Geographic distribution: Asia (China and Korea), southeastern & north United States.

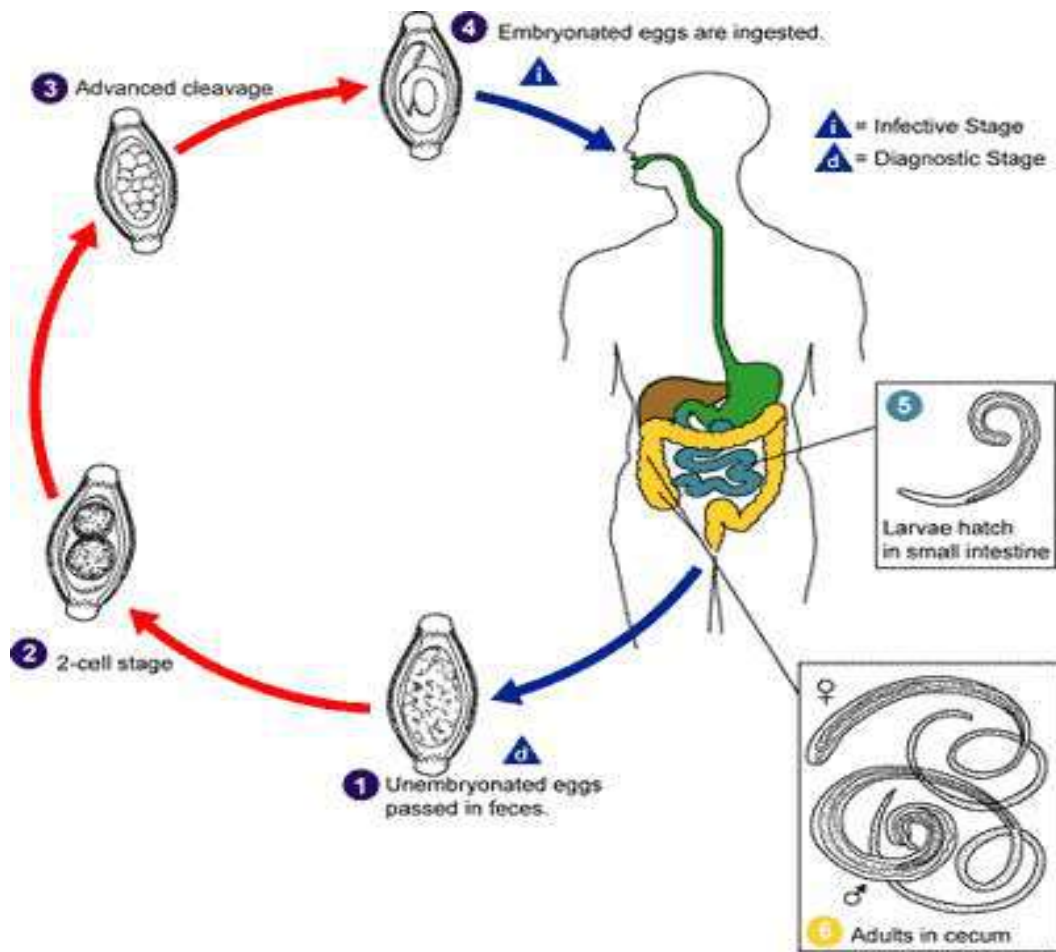
Morphology:

- Females are larger than males; approximately 35–50 mm long compared to 30–45 mm.
- The females have a bluntly round posterior end compared to their male counterparts with a coiled posterior end.
- The anterior, whip-like part is the esophageal end while shorter and thicker posterior part contains the parasite's intestines and reproductive organs.
- Eggs are barrel-shaped, brown, and have bipolar protuberances at each end.



Life cycle:

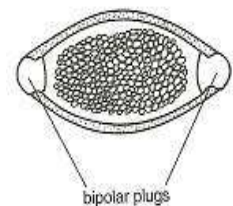
1. The female *T. trichiura* produces 2,000–10,000 single celled eggs per day. Eggs are deposited from human feces to soil, after 2-3 weeks, they become embryonated.
2. These embryonated infective eggs are ingested and hatch in the human small intestine. This is the location of growth and molting.
3. The infective larvae penetrate the villi and continue to develop in the small intestine.
4. The young worms move to the cecum and penetrate the mucosa and there they complete development to adult worms in the large intestine. Female begin to lay eggs after three months of maturity. Worms can live up to five years, during which time females can lay up to 20,000 eggs per day.



(Trichuris trichura life cycle)

Pathology and clinical features:

- **Light** infestations (<100 worms) are frequently **asymptomatic**.
- **Heavy** infestations may have **bloody diarrhea**.
- Long-standing blood loss may lead to **iron-deficiency anemia**.
- **Rectal prolapsed** is possible in severe cases.
- **Vitamin A** deficiency.
- Mechanical damage to the mucosa.
- Intestines inflammation.



Diagnosis: can be diagnosed easily using defecating proctogram.

Treatment: **Mebendazole albendazole**. **Iron** helps solve the iron deficiency and rectal prolapsed.

■ Class Secernentea

1. Order Ascaridida

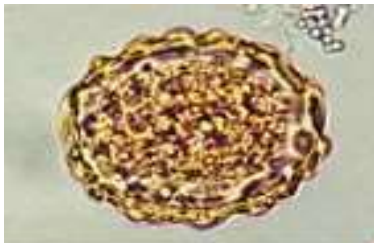★ *Ascaris lumbricoides* (giant roundworm)

Disease: Ascariasis

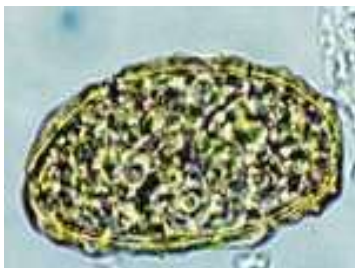Geographic distribution: worldwide.

Morphology:

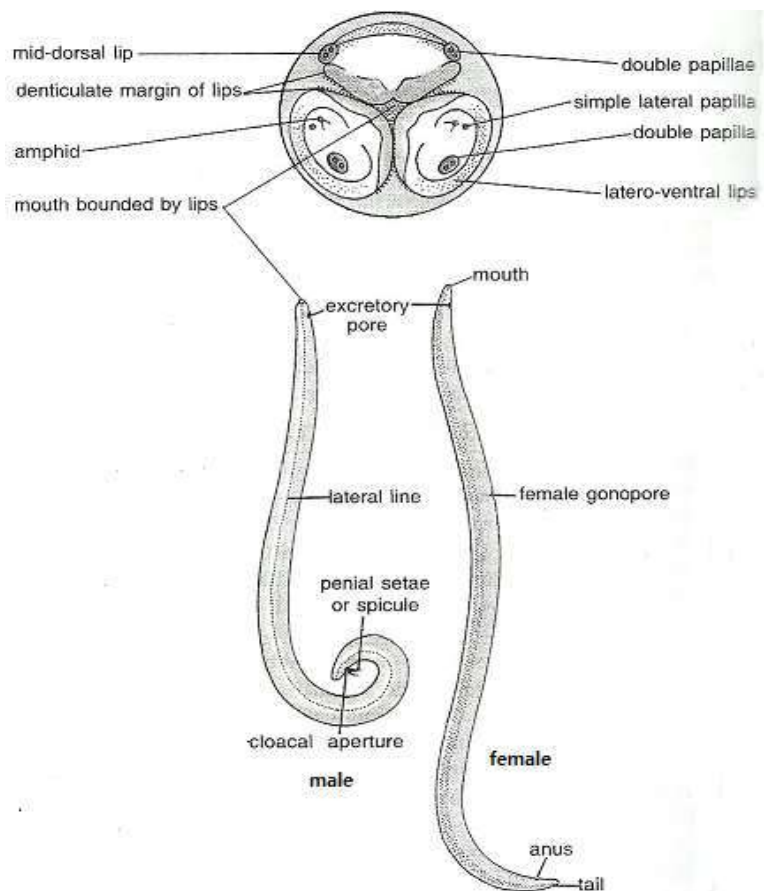
- Males are 2–4 mm in diameter and 15–31 cm long. Posterior end is curved ventrally and has a bluntly pointed tail.
- Females are 3–6 mm wide and 20–49 cm long. The vulva is located in the anterior end and accounts for about a third of its body length.
- Uteri contain up to 27 million eggs at a time with 200,000 being laid per day.
- Fertilized eggs are oval to round in shape and are 45-75 μm long by 35-50 μm wide with a thick outer shell and a lipid layer, which makes them resistant to the effects of acids and alkalis. Unfertilized eggs measure (88-94 μm x 44 μm).



Fertilized egg

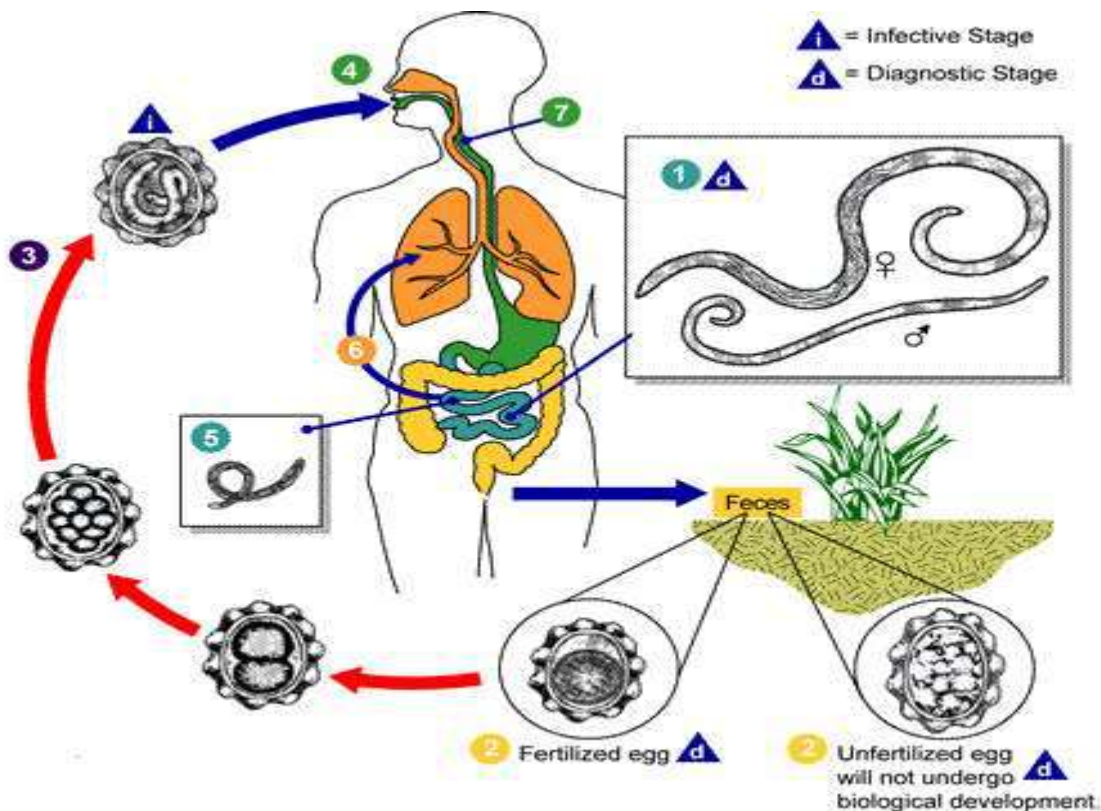


Unfertilized egg



Life cycle:

1. In small intestine, adult male and female worms mature. Fertilization can occur and the female produces as many as 200,000 eggs per day.
2. These fertilized eggs become infectious after 2 weeks in soil; they can persist in soil for 10 years or more.
3. Infections in humans occur when an ingested infective egg releases a larval worm that penetrates the wall of the duodenum and enters the blood stream.
4. A Larvae carried to the liver and heart, and then enter pulmonary circulation to break free in the alveoli, where it grows and molts.
5. In 3 weeks, the larvae pass from the respiratory system to be coughed up, swallowed, and thus returned to the small intestine, where they mature to adult worms.



(*Ascaris lumbricoides* life cycle)

Pathology and clinical features:

- 1) Patients can remain asymptomatic for very long periods of time. As **larval** stages travel through the body, they may cause:
 - Visceral damage.
 - Inflammation.
 - Enlargement of the liver or spleen.
 - Toxicity.
 - Pneumonia.

- 2) A heavy **worm** infestation may cause:
 - Nutritional deficiency.
 - Obstruction of the bile or pancreatic duct.
 - The worms caused torsion and gangrene of the ileum, which cause death.

Diagnosis: The appearance of worm or eggs in feces.

Treatment: Infections can be treated with drugs called **Ascaricides**. The treatment of choice is **Mebendazole**. **Nitazoxanide** and **Ivermectin** also be used.

2. Order Oxyurida



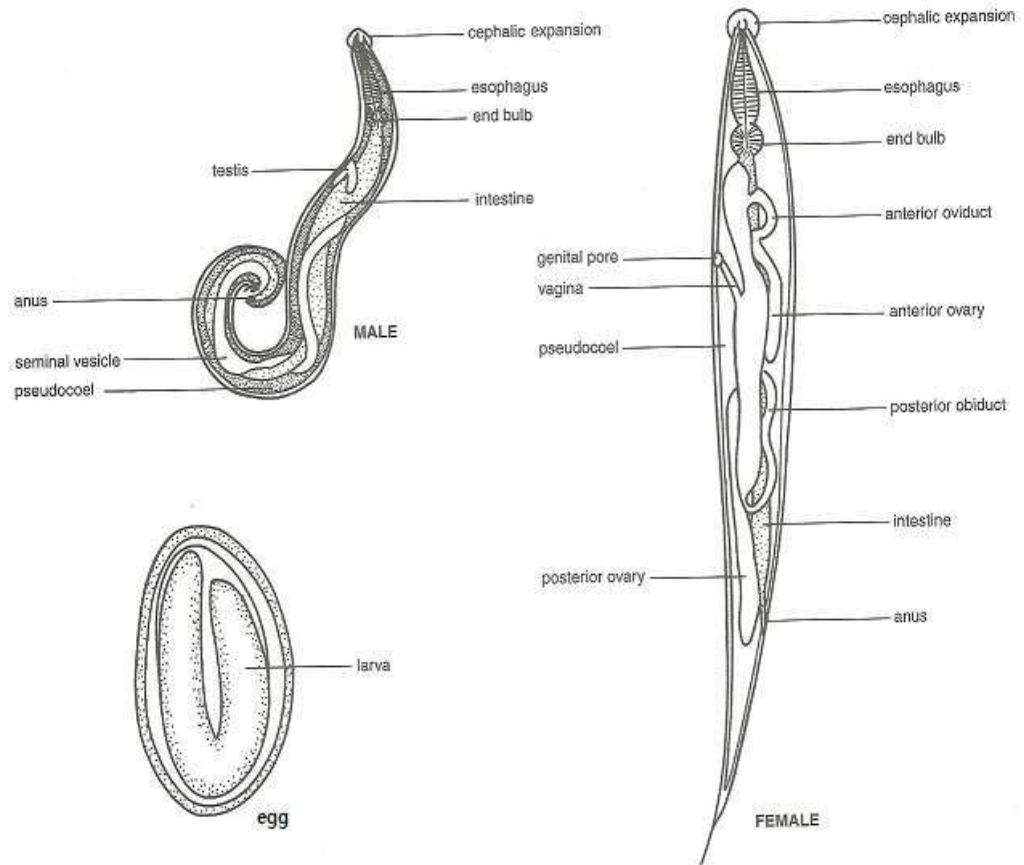
Enterobius vermicularis (pinworm, threadworm or seat worm)

Disease: Enterobiasis.

Geographic distribution: worldwide distribution

Morphology:

- White, small and delicate nematode .
- The adult female has a sharply pointed posterior end, is 8 to 13 mm long, and 0.5 mm thick.
- The adult male is considerably smaller, measuring 2 to 5 mm long and 0.2 mm thick, and has a curved posterior end.
- The eggs are translucent and have a surface that adheres to environmental objects. They measure (50 - 60µm x20 -30 µm), and have a thick shell that is flattened on one side. Eggs may contain a developing embryo or a fully developed pinworm larva.



Life cycle:

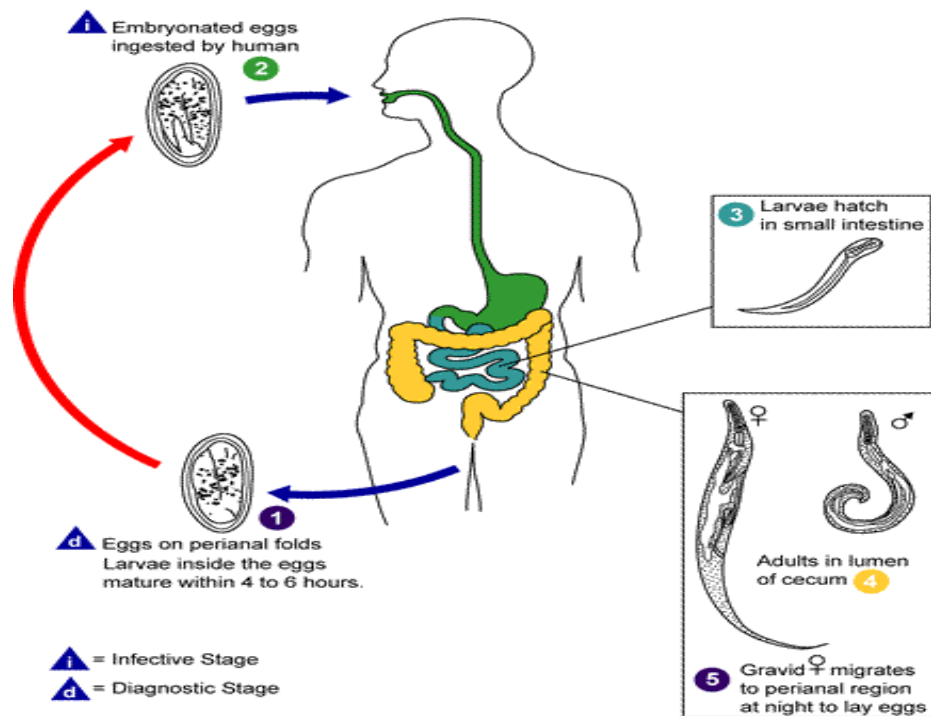
The entire life cycle from egg to adult takes place in the human gastrointestinal tract of a single human host.

- 1) The life cycle begins with eggs being ingested. The eggs hatch in the duodenum.
- 2) The emerging larvae grow rapidly and migrate through the small intestine towards the colon. During this migration they molt twice and become adults.
- 3) Females survive for 5 to 13 weeks, and males about 7 weeks. The male and female pinworms mate in the ileum, whereafter the male pinworms usually die, and are passed out with stool.
- 4) The gravid female pinworms settle in the ileum, caecum, appendix and ascending colon, where they attach themselves to the mucosa and ingest colonic contents. The number of eggs in a gravid female pinworm ranges from about 11,000 to 16,000.
- 5) The egg-laying process begins 5 weeks after initial ingestion of pinworm eggs by the human host. The gravid female pinworms migrate through the colon towards the rectum. They emerge from the anus, and while moving on

the skin near the anus (to obtain the oxygen necessary for the maturation of the eggs) , they deposit eggs through:

- Contracting and expelling the eggs.
- Dying and then disintegrating.
- Bodily rupture due to the host scratching the worm.

After depositing the eggs, the female becomes opaque and dies.



(*Enterobius vermicularis* life cycle)

Pathology and clinical features:

One third of individuals with pinworm infection are totally asymptomatic. The main symptoms are:

- + Pruritus ani and perineal pruritus.
- + Itching in and around the anus and around the perineum (mainly during the night) caused by the female migrating to lay eggs around the anus.
- + Skin inflammation due to continuously scratching the area around the anus, which further results in tearing of the skin and complications such as secondary bacterial infections, including bacterial dermatitis.
- + Restlessness.
- + Anorexia .
- + Weight loss.
- + In women they may move onto the vulva and into the vagina, this can cause vulvovaginitis.

Diagnosis:

Diagnosis depends on finding the **eggs or the adult** pinworms. Eggs are invisible to the naked eye, but they can be seen using a **low-power microscope**. On the other hand, the light-yellowish thread-like adult pinworms are clearly visually detectable, usually during the night when they move near the anus, or on toilet paper. Transparent adhesive tape (**Scotch Tape**) applied on the anal area will pick up deposited eggs, and diagnosis can be made by examining the tape with a microscope. This test is most successful if done every morning for several days, because the females do not lay eggs every day, and the number of eggs varies.

Treatment:

Although **hygiene** plays a role, medication is the chief treatment. Because the pharmaceutical drugs kill the adult pinworms but not the eggs, retreatment is recommended in 2 weeks. If one household member spreads the eggs to another, it will be a matter of 2-3 weeks before those eggs become adult worms and thus amenable to treatment. **Albendazole** and **Mebendazole** are the most effective.

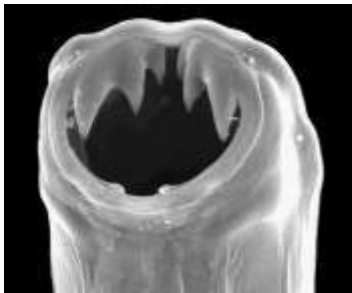Hookworm



Necator americanus and *Ancylostoma duodenale*

Scientific classification

Kingdom: Animalia
 Phylum: Nematoda
 Class: Secernentea
 Order: Strongiloidae
 Family: Ancylostomatidae
 Genus: Necator/Ancylostoma

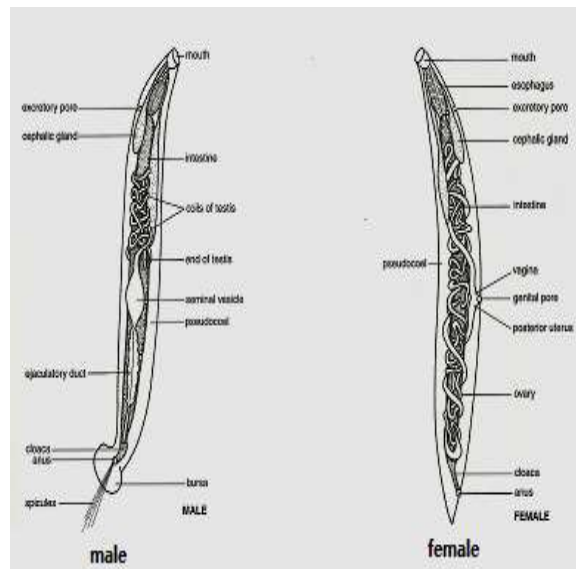


The hookworm is a parasitic nematode that lives in the small intestine of its host, which may be a mammal such as a dog, cat, or human. Two species of hookworms commonly infect humans, *Ancylostoma duodenale* and *Necator americanus*.

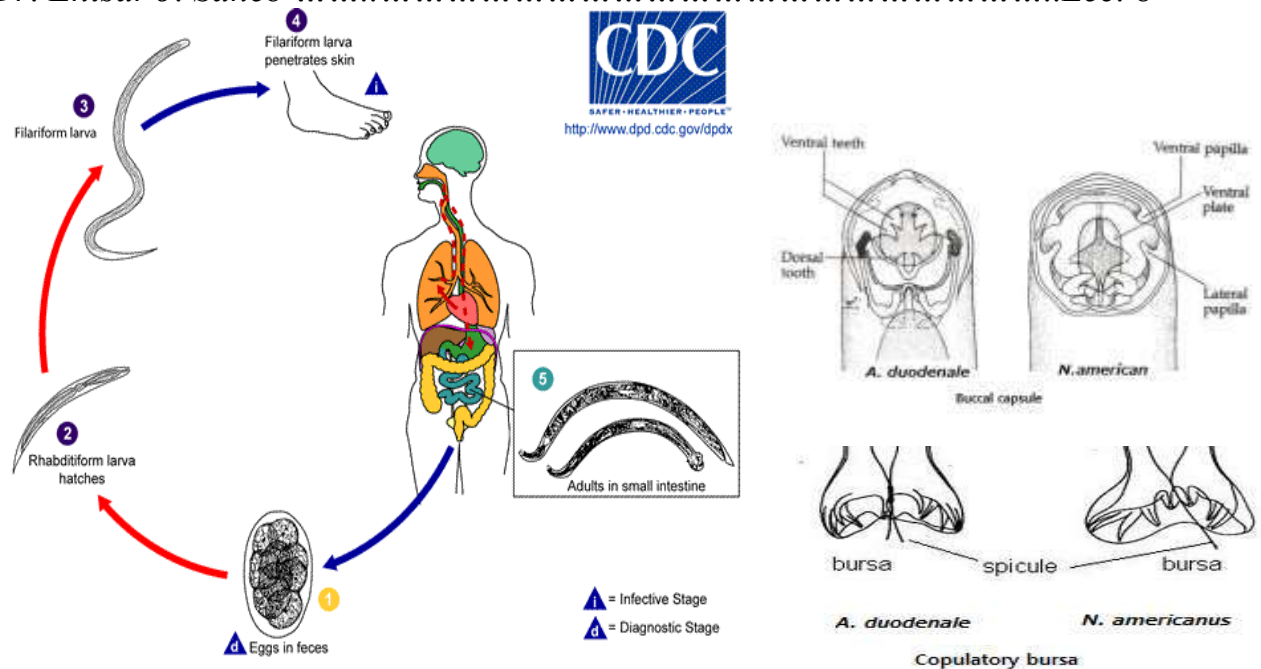
A. duodenale predominates in the Middle East, North Africa, India and (formerly) in southern Europe, while *N. americanus* predominates in the Americas, Sub-Saharan Africa, Southeast Asia, China, and Indonesia.

Morphology

A. duodenale worms are grayish white or pinkish with the head slightly bent in relation to the rest of the body. This bend forms a definitive hook shape at the anterior end for which hookworms are named. They possess well developed mouths with two pairs of teeth. While males measure approximately one centimeter by 0.5 millimeter, the females are often longer. Additionally, males can be distinguished from females based on the presence of a prominent posterior copulatory bursa.



N. americanus is very similar in morphology to *A. duodenale*. *N. americanus* is generally smaller than *A. duodenale* with males usually 5 to 9 mm long and females about 1 cm long. Whereas *A. duodenale* possess two pairs of teeth, *N. americanus* possesses a pair of cutting plates in the buccal capsule. Additionally, the hook shape is much more defined in *Necator* than in *Ancylostoma*.



Hookworm life cycle

Hookworm life cycle

N. americanus and *A. duodenale* eggs can be found in warm, moist soil where they will eventually hatch into first stage larvae, or L1.

L1, the feeding non-infective rhabdito form stage, will feed on soil microbes Eventually molt into second stage larvae, L2.

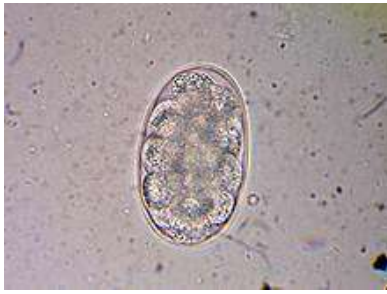L2, which is also in the rhabdito form stage, will feed for approximately 7 days and then molt into the third stage larvae, or L3.

L3 is the filari form stage of the parasite, that is, the non-feeding infective form of the larvae. The L3 larvae are extremely motile and will seek higher ground to increase their chances of penetrating the skin of a human host. The L3 larvae can survive up to 2 weeks without finding a host. While *N. americanus* larvae only infect through penetration of skin, *A. duodenale* can infect both through penetration as well as orally. After the L3 larvae have successfully entered the host, the larvae then travel through the subcutaneous venules and lymphatic vessels of the human host. Eventually, the L3 larvae enter the lungs through the pulmonary capillaries and break out into the alveoli. They will then travel up the trachea to be coughed and swallowed by the host. **After being swallowed, the L3 larvae are then found in the small intestine where they molt into the L4, or adult worm stage.**

The entire process from skin penetration to adult development takes about 5–9 weeks. The female adult worms will release eggs (*N. Americanus* about 9,000-10,000 eggs/day and *A. duodenale* 25,000-30,000 eggs/day) which are passed in the feces of the human host. These eggs will hatch in the environment within several days and the cycle with start anew.

The incubation period can vary between a few weeks to many months and is largely dependent on the number of Hookworm parasites an individual is infected with.

Diagnosis



Hookworm egg

Diagnosis depends on finding characteristic worm eggs on microscopic examination of the stools, although this is not possible in early infection. The eggs are oval or elliptical, measuring 60 μm by 40 μm , colourless, not bile stained and with a thin transparent hyaline shell membrane.

Treatment

The hookworm can be treated with local cryotherapy when it is still in the skin. Albendazole is effective both in the intestinal stage and during the stage the parasite is still migrating under the skin.

Symptoms

Third-stage larvae are capable of rapid penetration into normal skin, most commonly of the feet. Transmission occurs after 5 or more minutes of skin contact with soil that contains viable larvae. They puncture and feed on mucosal capillaries in the jejunum. The larvae burrow into venules and embolize the lungs, where they break into alveoli. Hookworm is one of the causes of the pulmonary infiltrates and **eosinophilia [PIE] syndrome**) Coughing brings the larvae to the mouth, where swallowing transports them to the intestine.

- Early symptoms of hookworm infection are proportional to the intensity of exposure.
- *Necator* produces a local irritation, termed **ground itch**, at the site of skin invasion. An intensely pruritic, erythematous, or vesicular rash usually appears on the feet or hands. This should be distinguished from a **creeping eruption** due to skin migration of the cat or dog hookworm *Ancylostoma braziliense*.
- Severe infection with either *A. duodenale* or *N. americanus* may produce pneumonitis (**Loeffler like syndrome**) that manifests as cough, fever, and malaise.
- As worms mature in the jejunum, patients may experience **diarrhea**, vague **abdominal pain, colic, and/or nausea**. These symptoms are more common with initial exposures than with subsequent exposures.
- Patients with severe iron deficiency anemia may present with headache, palpitations, dyspnea, and edema.

Quick Facts

Genus and Species	<i>Necator americanus</i>	<i>Ancylostoma duodenale</i>
Common Name	New world hookworm	Old world hookworm
Etiologic Agent	Necatoriasis, Uncinariasis	Ancylostomiasis,
Infective stage	Filariform larva	Filariform larva
Definitive Host	Human	Human
Portal of Entry	Usually via skin penetration rather than ingestion	Usually via ingestion rather than skin penetration
Mode of Transmission	Skin > Mouth	Mouth > Skin
Habitat	Small Intestine (jejunum, ileum)	Small Intestine (duodenum, jejunum)
Pathogenic Stage	L3 Larva	L3 Larva
Maturation time in host	49-56 (days)	53
Mode of Attachment	Oral attachment to mucosa by sucking	Same
Mode of Nutrition	Sucking and Ingesting of blood	Same
Pathogenesis	Larva – ground / dew itch, creeping eruption Adult – Microcytic, Hypochromic Anemia	Same
Laboratory diagnosis	Concentration and Direct Fecal Smear	Same
Treatment	Albendazole, Mebendazole,	Same
Length of adult hookworm (mm)	5-9 for males; 9-11 for females	8-11 for males; 10-13 for females
Shape	Head curved opposite to curvature of body, giving a hooked appearance to anterior end	Head continuous in same direction as the body
Egg output per female worm per day	5,000-10,000	10,000-25,000
Blood loss per worm per day (ml)	0.03	0.15-0.23
Temperature at which 90% of eggs hatch (C)	20-35	15-35
Diagnostic Feature– Adult	Semi-lunar cutting plate; Bipartite dorsal ray	Male – Tripartite dorsal ray
Diagnostic Feature - Egg	In Morula	Same

Cutaneous Larva Migrans

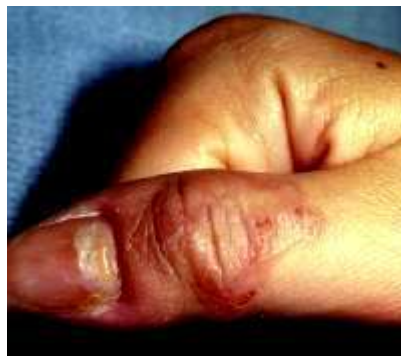Cutaneous larva migrans ("CLM") (**creeping eruption**) is a skin disease in humans, caused by the larvae of various nematode parasites, the most common of which in the Americas is *Ancylostoma braziliense* (hookworm of wild and domestic dogs and cats) is the most common cause. It can be found in the central and southern United States, Central America, South America, and the Caribbean. *Ancylostoma caninum* (dog hookworm) is found in Australia.

Pathophysiology

In cutaneous larva migrans (CLM), the life cycle of the parasites begins when eggs are passed from animal feces into warm, moist, sandy soil, where the larvae hatch. They initially feed on soil bacteria and molt twice before the infective third stage. By using their proteases, larvae penetrate through follicles, fissures, or intact skin of the new host. After penetrating the stratum corneum, the larvae shed their natural cuticle. Usually, they begin migration within a few days. In their natural animal hosts, the larvae of cutaneous larva migrans are able to penetrate into the dermis and are transported via the lymphatic and venous systems to the lungs. They break through into the alveoli and migrate to the trachea, where they are swallowed. In the intestine they mature sexually, and the cycle begins again as their eggs are excreted. Humans are accidental hosts, and the larvae are believed to lack the collagenase enzymes required to penetrate the basement membrane to invade the dermis. Therefore, cutaneous larva migrans remains limited to the skin when humans are infected.

Physical

- Pruritic, erythematous, edematous papules
- Serpiginous (snakelike), slightly elevated, erythematous tunnels that are 2- to 3-mm wide and track 3-4 cm from the penetration site
- Systemic signs include peripheral eosinophilia (**Loeffler syndrome**), migratory pulmonary infiltrates, and increased immunoglobulin E (IgE) levels, but are rarely seen.
- Lesions are typically distributed on the distal lower extremities, including the dorsa of the feet and the interdigital spaces of the toes, but can also occur in the anogenital region, the buttocks, the hands, and the knees.



Cutaneous larva migrans on the right thumb

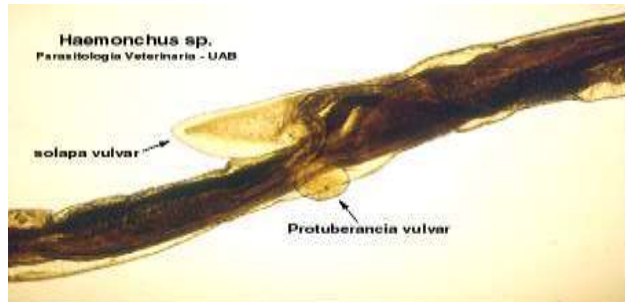
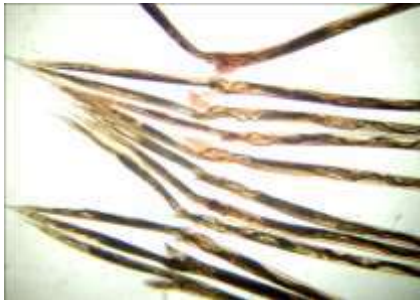

Haemonchus contortus

Haemonchus contortus, also known as red stomach worm, wire worm or Barber's pole worm, is very common parasite and one the most pathogenic nematode of ruminants. Adult worms are attached to abomasal mucosa and feed on the blood. The infection, called Haemonchosis, causes large economic losses for farmers around the world, especially for those living in the warmer climates.

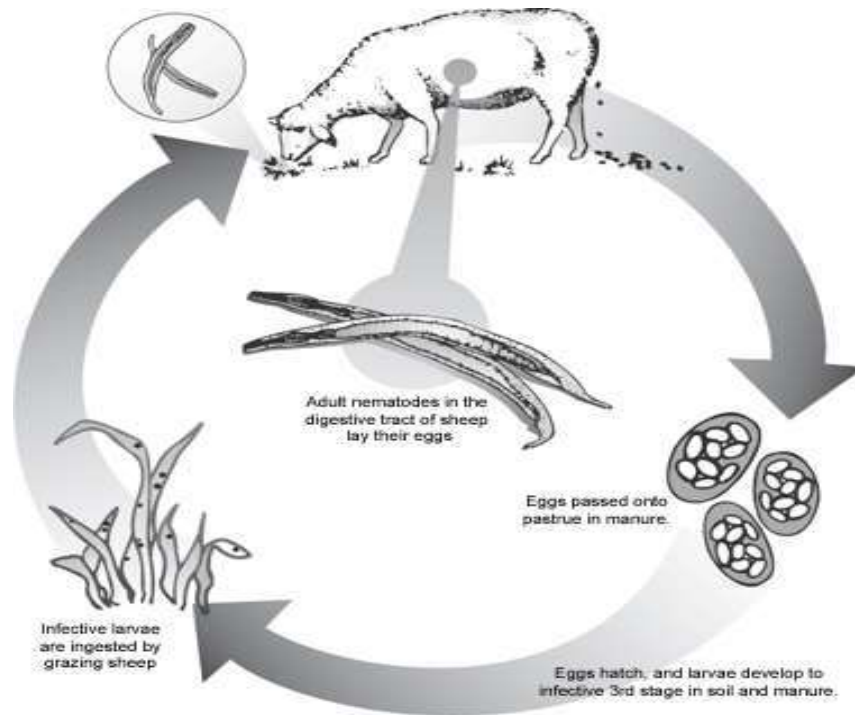
Morphology:

The adult female is 18–30 mm long and is easily recognized by its trademark “barber pole” coloration. The red and white appearance is due to the fact the *Haemonchus contortus* is a blood feeder and is due to the white ovaries that coil around the intestines which are filled with blood. The male adult worm is much smaller at 10–20 mm long and displays the distinct feature of a well-developed copulatory bursa, containing an asymmetrical dorsal lobe and a Y shaped dorsal ray.



Life cycle:

1. The adult female worm can release between 5,000 – 10,000 **eggs** which will be passed out in the feces.
2. Eggs then develop in moist conditions in the feces and continue to develop into the **L1 (rhabditiform)**, and **L2 juvenile** stages by feeding on bacteria in the dung.
3. The L2 rhabditiform sheds its cuticle and then develops into the **L3 filiariform** infective larvae. The L3 has a protective cuticle, however under dry hot conditions will not survive long.
4. The L3 then crawl up the blades of wet grass and wait to be ingested by a grazing animal. Sheep, goats and other ruminants become infected when they graze and eat grasses containing the L3 infecting larvae.
5. The infecting larvae pass through the first three stomachs to reach the abomasum. There the L3 sheds its cuticle and burrows into the internal layer of the abomasum where they develop into **L4**, usually within 48 hours, or pre-adult larvae.
6. The L4 larvae then molt and develop into the **L5 adult form**. The male and female adults mate and live in the abomasum, where they feed upon the blood.



Life cycle

Pathogenicity:

The nematode piercing the abomasum causes a number of significant complications in the infected ruminants that can **lead to death**. The infected animals can display severe **dehydration, diarrhea, unthrifty appearance, lethargy, depressed low energy behavior, rough hair coat and uncoordinated movements**. Furthermore, significantly **reduced growth and poor reproductive performance** has been observed. The accumulation of fluid in the abdomen, gut wall, thoracic cavity and submandibular tissue – a phenomenon commonly called "**bottle jaw**", also is a common association with this infection. Severe **blood loss, white mucous membranes, and anemia** are common complications of the infection.



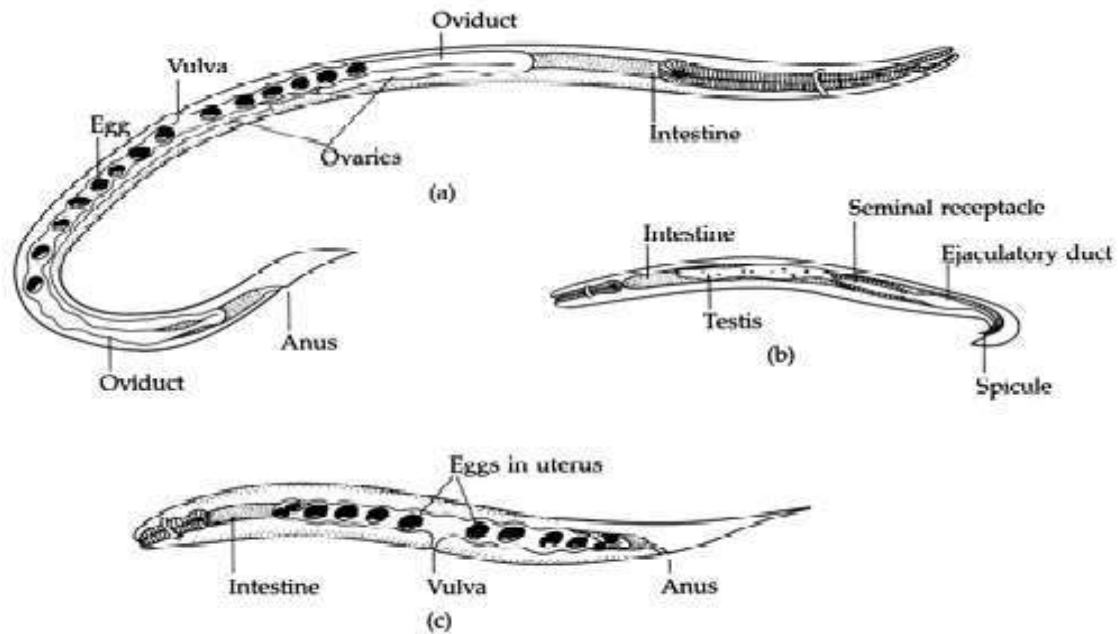
***Strongyloides stercoralis* (Threadworm)**

Disease: Strongyloidiasis

Geographic distribution: Vietnam, Cambodia, Laos, Japan, Brazil, Central America and Australia.

Morphology:

- Whereas males grow to only about 0.9 mm in length, females can be anywhere from 2.0 to 2.5 mm.
- Both genders also possess a tiny buccal capsule and cylindrical esophagus without a posterior bulb.
- In the free-living stage, the esophagi of both sexes are rhabditiform.
- Males can be distinguished from their female counterparts by two structures: the spicules and gubernaculum.



Strongyloides stercoralis (a) parasitic female (b) free-living male (c) free-living female.

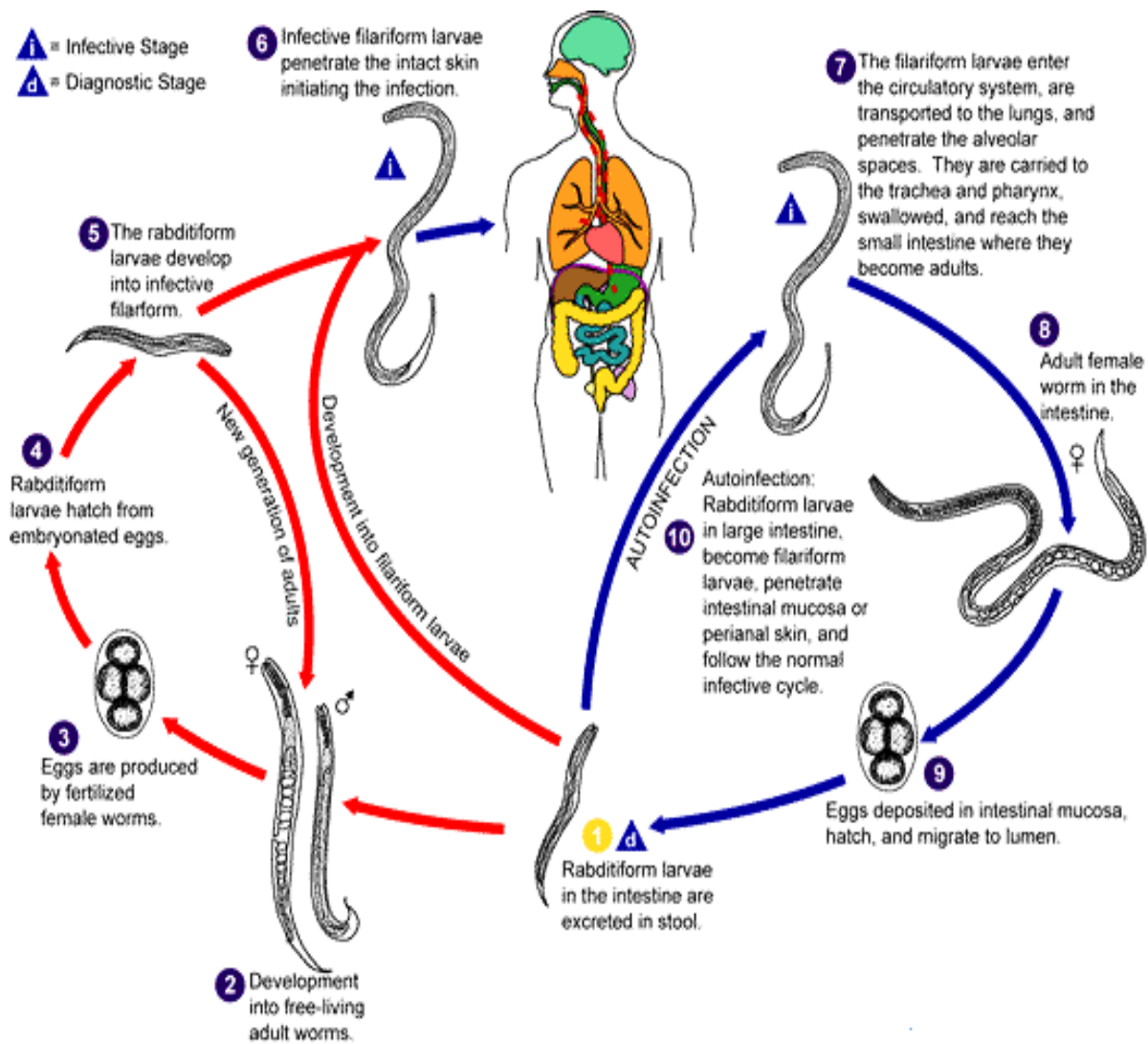
Life cycle: *S. stercoralis* has a life cycle that consists of:

- Parasitic generation (has a homogenic life cycle).
- Free-living generation (has a heterogonic life cycle).

The heterogonic life cycle is advantageous to the parasite because it allows reproduction for one or more generations in the absence of a host.

1. L1 larvae (rhabditiform larvae) pass out in the feces and develop on the ground to infective larvae (filariform larvae). This development can occur via two routes:

- a. Directly from L1 to infective larvae via three molts.



(Life cycle of *Strongyloides stercoralis*)

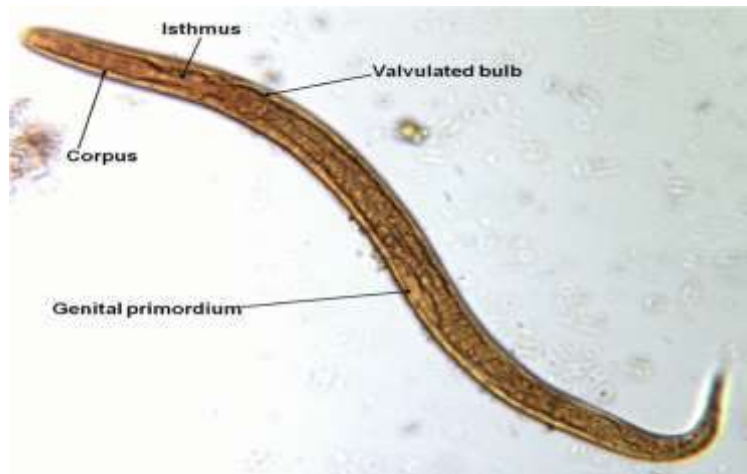
- b. Indirectly, the development of free-living adults which mate; the female - lays eggs -hatch and develop into infective larvae. The free-living males and females of *S. stercoralis* die after one generation; they do not persist in the soil.
- The infectious larvae penetrate the skin when there is contact with the soil.
 - Some of them enter the blood vessels to the lungs, where they enter the alveoli. They are then coughed up and swallowed into the gut, where they parasitize the intestinal mucosa (duodenum and jejunum).
 - Only females will reach reproductive adulthood in the intestine. Female reproduce through **parthenogenesis**. The eggs hatch in the intestine and young larvae are then excreted in the feces.

Pathology and clinical features:

- + Dermatitis: swelling, itching, and mild hemorrhage at the site where the skin has been penetrated.
- + If the parasite reaches the lungs, the chest may feel as if it is burning, and wheezing and coughing may result, along with pneumonia-like symptoms (Löffler's syndrome).
- + Eventually, the intestines could be invaded, leading to burning pain, tissue damage, sepsis, and ulcers. In severe cases, edema may result in obstruction of the intestinal tract as well as loss of peristaltic contractions.

Diagnosis

- I. Locating juvenile larvae, either rhabditiform or filariform, in recent stool samples will confirm the presence of this parasite.



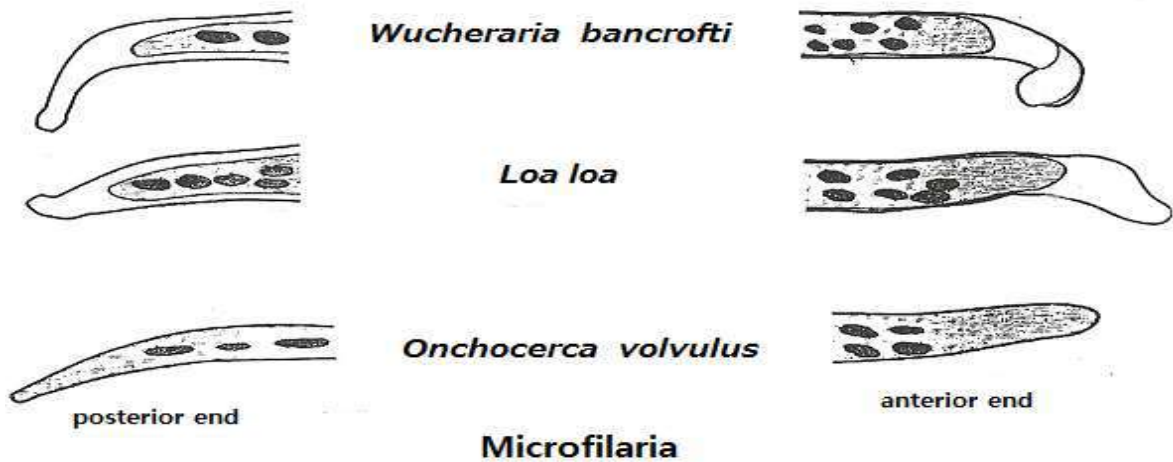- II. Serodiagnosis through ELISA.
- III. Duodenal fumigation.

Treatment

Ivermectin , Albendazole

Blood and tissue Nematodes

Filarial worms (*Wucheraria bancrofti*, *Loa loa*, *Onchocerca volvulus*)



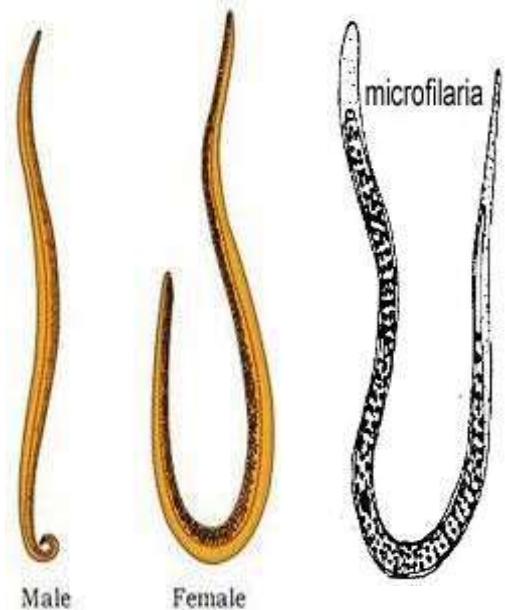Wucheraria bancrofti

It is a parasitic filarial nematode spread by a mosquito vector. It causes **lymphatic filariasis**, an infection of the lymphatic system which can develop into a chronic disease called **elephantiasis**.

Geographic distribution: Africa, the Nile Delta, Turkey, India, the East Indies, Southeast Asia, Philippines, Oceanic Islands, Australia, and parts of South America.

Morphology:

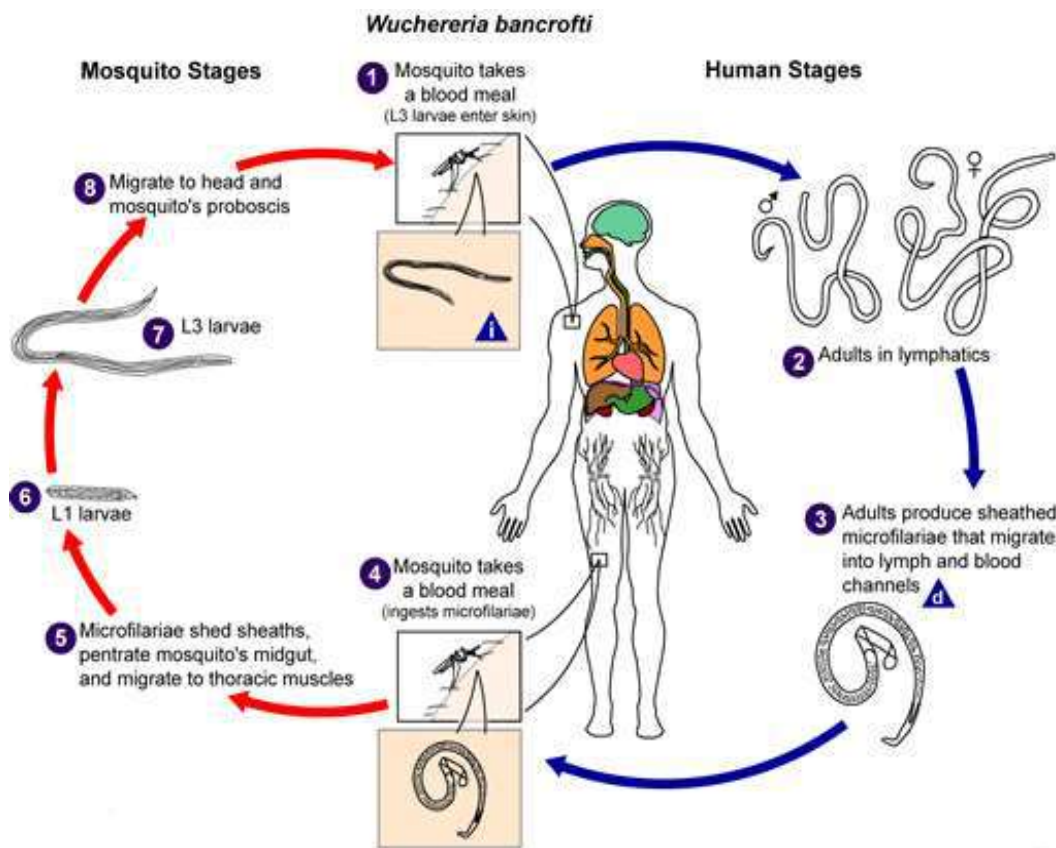
- The adult worm is long, slender, and smooth with rounded ends. It has a short cephalic region, dispersed nuclei throughout its body cavity, **with no nuclei at the tail tip**.
- The male worm is 40 mm long and 100 μm wide, and features a curved tail.
- The female is 6 - 10 cm long and 300 μm wide, nearly three times larger in diameter than the male.
- Females are **ovoviviparous** and can produce thousands of juveniles known as **microfilariae**.
- Microfilariae of *W. bancrofti* retain the egg membrane as a sheath and are often considered advanced embryos. They migrate between the deep and the peripheral circulation. During the day they are present in the deep veins and during the night (from 10 p.m. to 2 a.m) they migrate to the peripheral circulation (nocturnal periodicity).



Life cycle

W. bancrofti carry out their life cycle in two hosts. Human beings serve as the definitive host and mosquitoes as their intermediate hosts. The adult parasites reside in the lymphatics of the human host.

1. The microfilariae are transferred into a vector; (the mosquito species: *Culex*, *Anopheles*, *Mansonia*, and *Aedes*), then mature into motile larvae called juveniles.
2. When the mosquito has its next blood meal, *W. bancrofti* is egested via the mosquito's proboscis into the blood stream of the new human host.
3. The larvae move through the **Lymphatic system** to regional lymph nodes, predominantly in the **legs and genital area**.
4. The larvae develop into adult worms over the course of a year and reach sexual maturity in the afferent lymphatic vessels.
5. After mating, the adult female worm can produce thousands of microfilariae that migrate into the bloodstream. A mosquito vector can bite the infected human host, ingest the microfilariae, and thus repeat the life cycle of *W. bancrofti*.



(Life cycle of *Wuchereria bancrofti*)

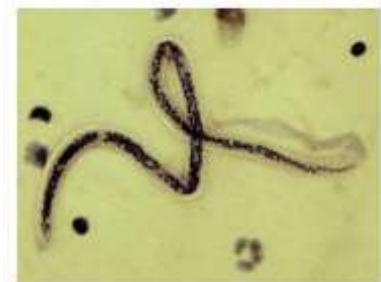Pathology and clinical features

After infection, the worms will mature within 6–8 months; male and female worms will mate and then release the microfilariae. These microfilariae worms can be released for up to 10 years.

1. **Asymptomatic Phase:** consists of high microfilaremia infection and individuals show no symptoms of being infected. This can occur for years until the inflammatory reaction rises again.
2. **Inflammatory (Acute) Phase:** The antigens from the female adult worms elicit inflammatory responses. The worms in the lymph channels disrupt the flow of the lymph causing **lymphedema**: The individual will exhibit **fever, chills, skin infections, painful lymph nodes, and tender skin of the lymphedematous extremity**. These symptoms often lessen after 5–7 days. Other symptoms that may occur include: orchitis-inflammation of the testes, which is accompanied by painful immediate enlargement and epididymitis-which is the inflammation of the spermatic cord.
3. **Obstructive (Chronic) Phase:** Marked by lymph varices, lymph scrotum, hydrocele, chyluria (lymph in urine), and elephantiasis. Microfilariae are not normally present in this phase. Elephantiasis affects men mainly in the **legs, arms, and scrotum**. In women, the **legs and arms** are affected.

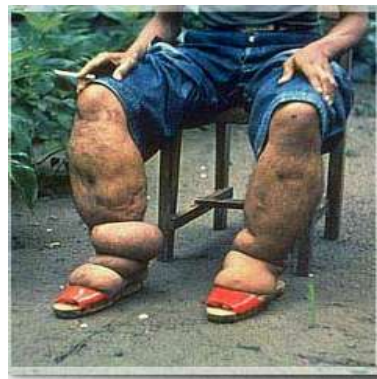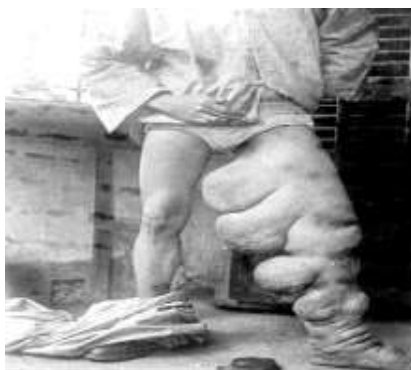Diagnosis:

- A blood smear is a simple diagnostic tool, provided that the blood sample is taken during the period in the day when the juveniles are in the peripheral circulation.
- Polymerase chain reaction PCR.
- Antigens detection.
- Ultrasonography to detect the adult worms.
- Dead, calcified worms can be detected by X-ray examinations.



Treatment:

The severe symptoms caused by the parasite can be avoided by cleansing the skin, surgery, or the use of therapeutic drugs, such as **Diethylcarbamazine, Ivermectin, or Albendazole**.



An infection in leg by *Wuchereria bancrofti*



Loa loa "eye worm"

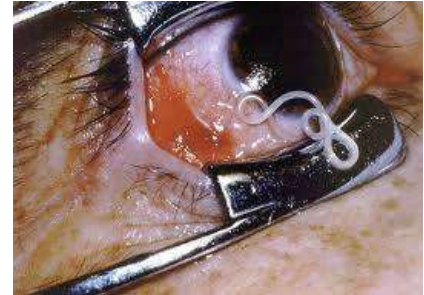
Disease: *Loa loa* filariasis, loiasis, Calabar swellings, Fugitive swelling, Tropical swelling and African eyeworm.

It is a **skin and eye** disease transmits through the bite of a **Deer fly** (*Chrysops spp*), the vectors migrate throughout the subcutaneous tissues of humans, occasionally crossing into subconjunctival tissues where it can be easily observed.

Geographic distribution: Africa, Sudan and India.

Morphology:

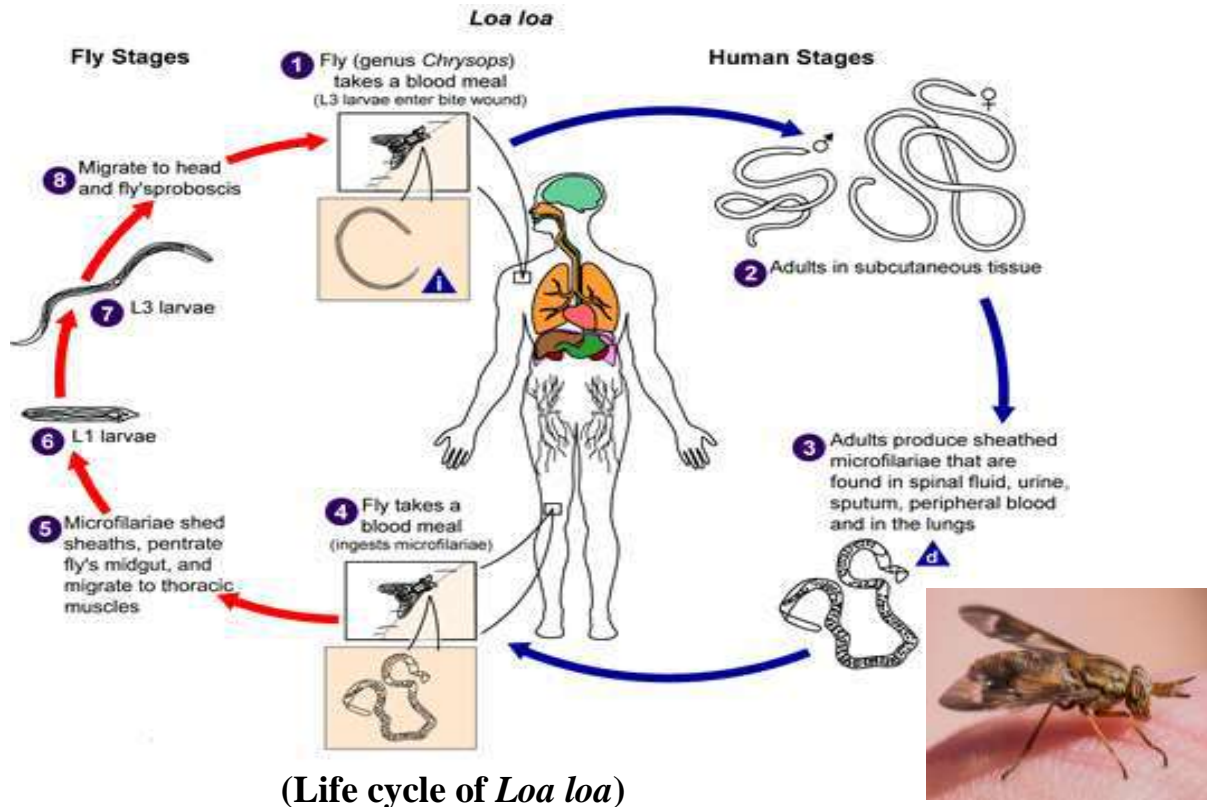
- Males smaller than females with the 30–34 mm long and 0.35-0.42 mm wide compared to 40–70 mm long and 0.5 mm wide.
- Adults live in the subcutaneous tissues of humans, where they mate and produce microfilaria.
- These microfilariae are 250-300µm long, 6-8µm wide, and can be distinguished morphologically from other filariae; they are sheathed and **contain body nuclei that extend to the tip of the tail.**



Life cycle:

- A vector fly (genus *Chrysops*, day-biting flies) bites an infected human host and ingests microfilariae during a blood meal.
- Microfilariae lose their sheaths and migrate from the fly's midgut through the hemocoel to the thoracic muscles of the fly.
- Microfilariae develop into first stage larvae L1, then third stage larvae L3.
- Third stage larvae (infective stage) travel to the proboscis of fly.
- An infected vector fly bites an uninfected human host and the third stage larvae penetrate the skin and enter human subcutaneous tissue.
- Larvae mature into adults, who produce microfilariae that have been found in spinal fluid, urine, peripheral blood, and lungs.

They are **diurnal periodicity**, during the day they are found in peripheral blood, but during the non-circulation phase, they are found in the lungs.



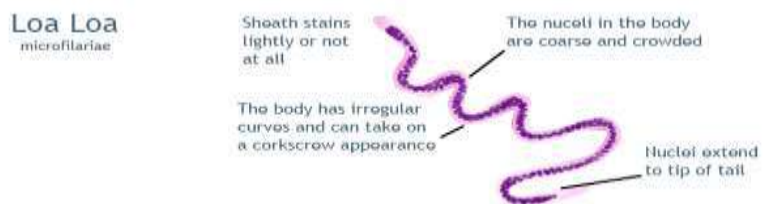
Pathology and clinical features:

Loa loa parasites infect human hosts by travelling through subcutaneous tissues such as the **back, chest, groin, scalp, and eye**.

- + These parasites cause inflammation in the skin wherever they travel. If a parasite stops in one place for a short period of time, the human host will suffer from local inflammation known as **Calabar swellings**. These often occur in the **wrist and ankle** joints but disappear as soon as the parasite begins to move again.
- + Parasites can also travel through and infect the eye, causing the swelling of the eye.
- + Common symptoms include itching, joint pain, and fatigue.

- Diagnosis:**
- I. The presence of microfilariae in the blood.
 - II. The presence of a worm in the eye.
 - III. The presence of skin swellings.

Treatment: Surgical removal of the Worm, or use of one of two drugs: **Diethylcarbamazine** or **Ivermectin**.





Onchocerca volvulus

Disease: **Onchocerciasis**, also known as **river blindness** and **Robles' Disease**.

Geographic distribution: most infections occur in sub-Saharan Africa, some cases in Yemen and isolated areas of Central and South America.

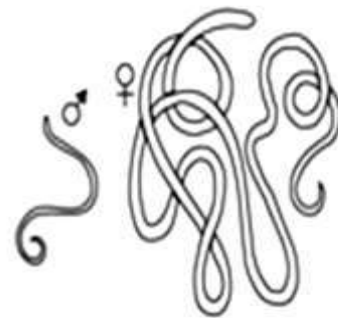Morphology:

- Adults' worms are entangled together in pairs or groups in subcutaneous tissues.
- Male worms measuring 23mm in length compared to 230-700mm in females.
- The vulva of the female is located just behind the posterior end of the esophagus. The male's posterior end is coiled ventrally and does not have alae.
- The microfilariae are not covered with membrane sheaths.

• *Onchocerca volvulus*

9-20 mm longitud

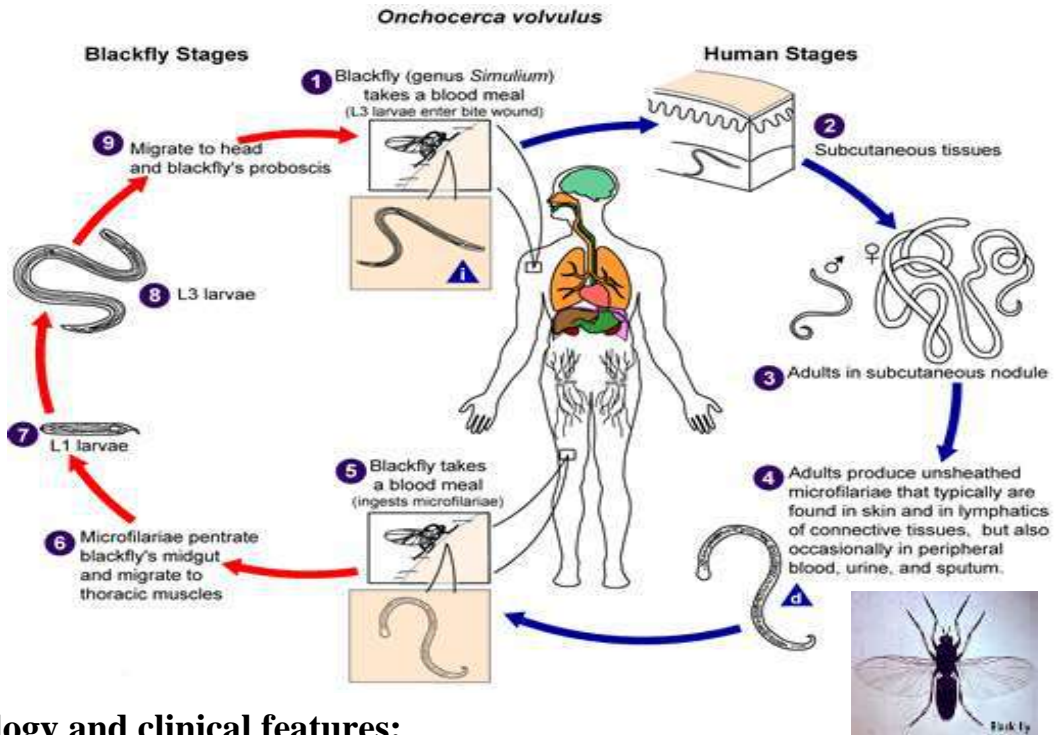
330-700mm longitud



Life cycle:

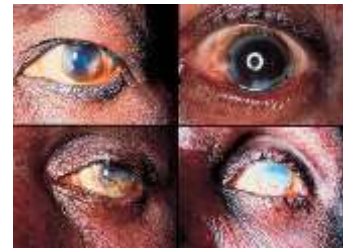Humans are the only definitive host for *O. volvulus*. The intermediate host or vector is the black fly (*Simulium*):

1. Female of black fly ingesting microfilaria when they take a blood meal from the dermis of an infected human host.
2. The microfilarias enter the gut and thoracic flight muscles of the black fly progressing into the first larval stage (**L1**).
3. The larvae mature into the second larval stage (**L2**) and move to the proboscis and found in **saliva** where they mature to third larval stage (**L3**) in about 7 days.
4. The black fly takes another blood meal passing the larvae into the next human host's blood.
5. The larvae migrate to the **subcutaneous tissue** and undergo two more molts. They form nodules as they mature into **adult worms** over 6-12 months.
6. Adult worms mate in the subcutaneous tissue to produce between 700 - 1500 microfilaria per day.
7. The **microfilarias** migrate to the skin during the day and the black flies only feed in the day, so the parasite is in a prime position for the female fly to ingest it. Black flies take blood meals to ingest microfilarias to restart the cycle.



Pathology and clinical features:

Prominent nodules appear if the adult worms are situated over a bone, such as at a joint or the skull. The locations of these nodules differ according to geographical region. In Central America, they are usually found above the waist, while in Africa they are usually below the waist. These distributions conform to the biting preferences of insect vectors in the two regions. As a result, microfilariae are concentrated at body parts where the insect vectors prefer to bite



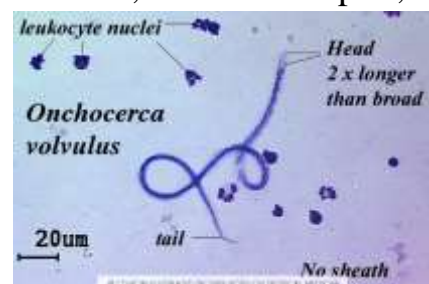
- **Adult worms** remain in subcutaneous nodules. Skin involvement consists of intense itching, swelling, and inflammation. Skin atrophy- loss of elasticity, skin resembles tissue paper, 'lizard skin' appearance;
- **The microfilariae** migrate to the surface of the cornea. Punctate keratitis occurs in the infected area. If the infection is chronic, sclerosing keratitis can occur, making the affected area become opaque. Over time the entire cornea may become opaque, thus leading to blindness.

Treatment

Ivermectin (trade name: **Mectizan**); two doses of ivermectin, six months apart,

Diagnosis:

1. (skin-snip microscopy) a sclerocorneal punch to obtain skin-tissue specimens from the iliac crests and search for microfilariae.
2. PCR.
3. ELISAs and antigen surveys.



***Dracunculus medinensis* (Guinea worm)**

("Little dragon from Medina") derives from its one-time high incidence in the city of Medina.

Disease: Dracunculiasis also called **guinea worm disease**.

Geographic distribution: Endemic in only four countries in Africa and India.

Morphology:

- It is among the longest nematodes infecting humans. The adult female is primarily larger than the adult male. The longest adult female recorded was 800 mm, while the adult male was only 40 mm.
- Mature female worms migrate along subcutaneous tissues to reach the skin below the knee:

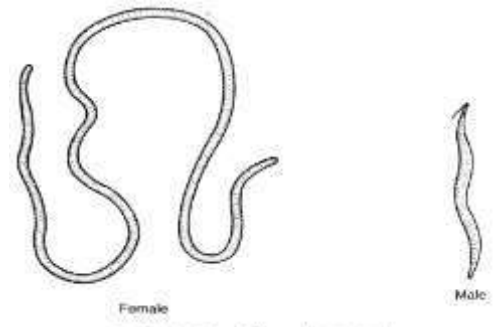
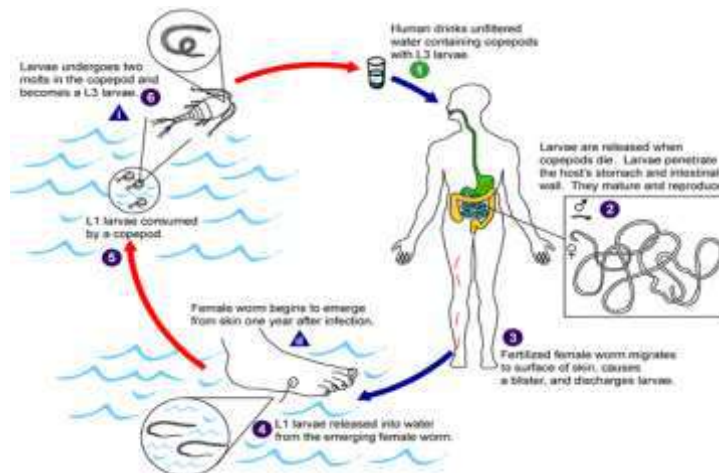


Fig. 701. Morphology of *Dracunculus medinensis*

Life cycle:

1. Humans become infected by drinking unfiltered water containing copepods that have been infected with *D. medinensis* larvae.
2. After ingestion, the copepods die and release larvae, which then penetrate the host's stomach, intestinal wall, and enter into the abdominal cavity.
3. After maturing, adult male worms die while the females migrate in the subcutaneous tissues towards the surface of the skin.
4. After about a year of infection, the female worm forms a blister on the skin, generally on the distal lower extremity (foot), which breaks open.
5. The patient then seeks to relieve the local discomfort by placing their foot in water, but when the lesion comes into contact with water, the female worm emerges and releases her larvae.
6. The larvae are then ingested by a copepod, and after two weeks and two molts the larvae become infectious. Ingestion of the copepods is the last stage that completes the cycle.



(Life cycle of *Dracunculus medinensis*)

Pathology and clinical features:

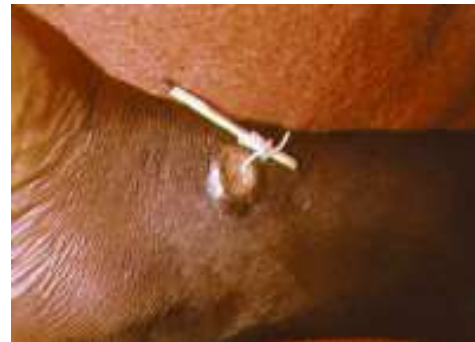- ✚ Female worms elicit allergic reactions during blister formation as they migrate to the skin, causing an intense burning pain. Such allergic reactions produce **rashes, nausea, diarrhea, dizziness, and localized edema.**
- ✚ Upon rupture of the blister, allergic reactions subside but skin ulcers form, through which the worm can protrude. Only when the worm is removed, is healing complete.
- ✚ Death of adult worms in joints can lead to **arthritis and paralysis** in the spinal cord.

Diagnosis:

Diagnosis of dracunculiasis is made by direct observation of the worms emerging from the lesions appearing on the legs of infected individuals and by microscopic examinations of the larvae.

Treatment:

- The traditional technique which involves winding the worm out on a stick has been a treatment used successfully for centuries.
- Surgically removing the worm.
- Drugs such as metronidazole may relieve symptoms, but not the worm.



Trichinella spiralis

- Kingdom: Animalia
- Phylum: Nematoda
- Class: Adenophorea
- Order: Trichurida
- Family: Trichinellidae
- Genus: *Trichinella*
- *Species: Trichinella spiralis* (Owen, 1835)

Trichinella spiralis is a nematode parasite, occurring in rats, pigs, and humans, and is responsible for the disease **trichinosis**. It is sometimes referred to as the "**pork worm**" due to it being found commonly in pork or rat products that are undercooked.

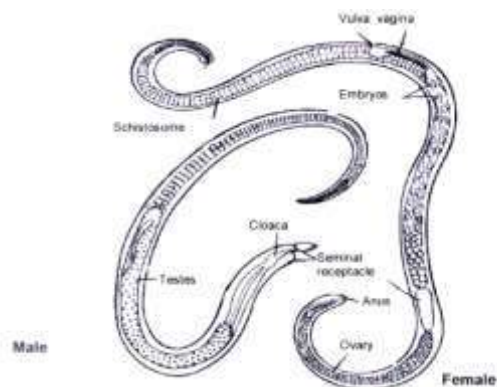
Trichinella species are the smallest nematode parasite of humans,. The small adult worms mature in the intestine of an intermediate host such as a pig. Humans can be infected by eating infected pork or wild carnivores such as fox, cat or bear.

Trichinosis, also called **trichinellosis**, or **trichiniasis**, is a parasitic disease caused by eating raw or undercooked pork infected with the larvae of a species of roundworm *Trichinella spiralis*, commonly called the trichina worm. Only three *Trichinella* species are known to cause trichinosis: ***T. spiralis***, ***T. nativa***, and ***T. britovi***. It is common in developing countries where meat fed to pigs is raw or undercooked, but many cases also come from developed countries in Europe and North America, where raw or undercooked pork and wild game may be consumed as delicacies.

Morphology:

❖ **Males** of *T. spiralis* measure between 1.4 mm to 1.6 mm long and are flat anteriorly than posteriorly. The anus can be found in the terminal (side) and they have a large copulatory pseudobursa on each side.

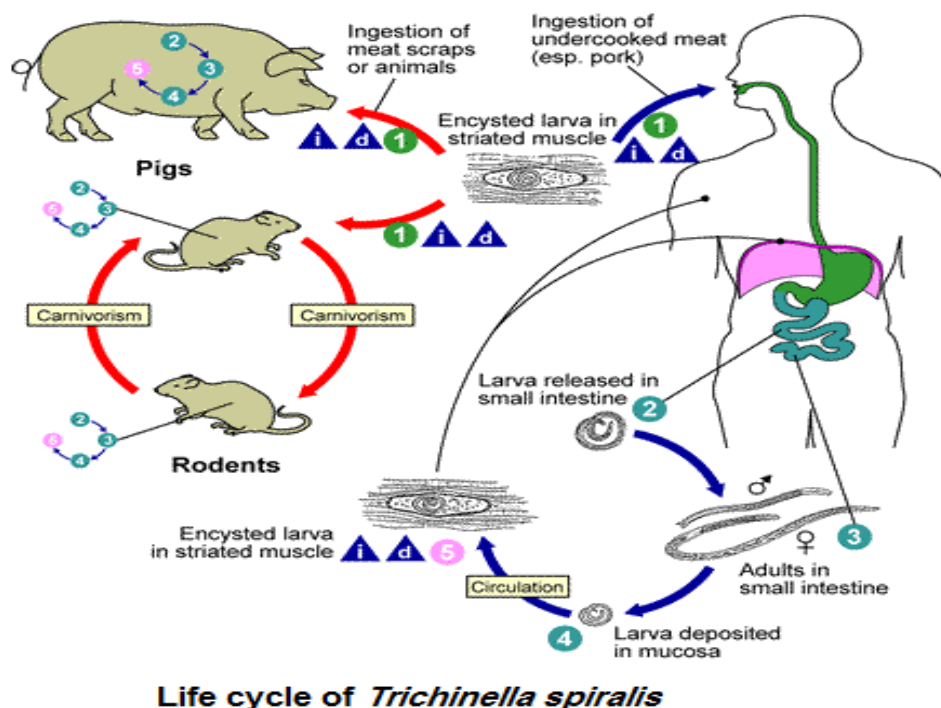
❖ **Females** of *T. spiralis* are about twice the size of the males and have an anus found terminally. The vulva is located near the esophagus. The single uterus of the female is filled with developing eggs in the posterior portion, while the **anterior portion contained the fully developed juveniles**. Female trichinella worms live for about six weeks and in that time can produce up to 1,500 larvae; where eventually a spent female dies and passes out of the host.



Life cycle:

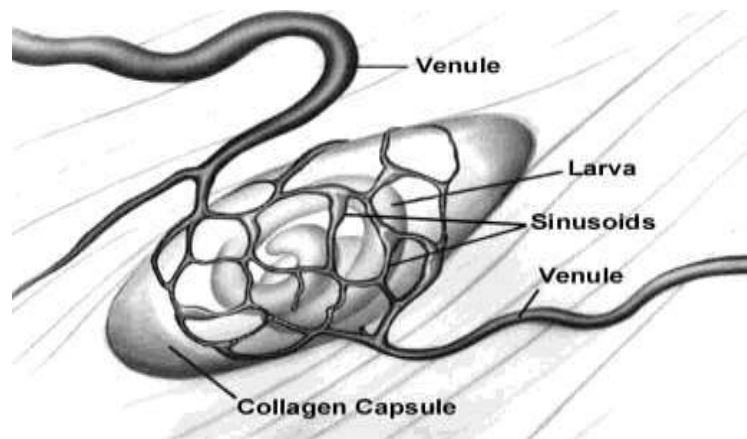
The typical life cycle for *Trichinella spiralis* involves humans, pigs, and rodents. Pigs become infected when they eat infectious cysts in raw meat, often pork or rats. Humans become infected when they eat raw or undercooked infected pork (domestic cycle).

1. After humans ingest the **cysts** from infected undercooked meat, pepsin and hydrochloric acid help free the larvae from the cysts.
2. The **larvae** then migrate to the small intestine where they molt four times before becoming **adults**.
3. Thirty to 34 hours after the cysts were originally ingested; the adults mate and within five days produce larvae. The worms can only reproduce for a limited period of time because the immune system will eventually expel them from the small intestine.
4. The larvae then use their piercing mouth part called the “**stylet**” to pass through the intestinal mucosa and enter the lymphatic vessels and then enter the bloodstream.
5. The larvae travel by capillaries to various organs such as the **retina, myocardium, or lymph nodes**—however, only larvae that migrate to **skeletal muscle** cells survive and encysted.
6. The larval host cell becomes a **nurse cell** in which the larvae will encapsulate. The development of a capillary network around the nurse cell completes encystations of the larvae.



Nurse Cell Formation: The Nurse cell is a unique consequence of the host cell’s association with the infectious L1 larva of *T. spiralis*. It presumably

functions to nourish it as well as protect it from host immune responses. The mature Nurse cell is morphologically distinct from any other mammalian cell type; no other pathological condition induces such a radically different, and yet functional cell. The Nurse cell-parasite complex can survive in the human host for up to 30 years, and in most other species of mammal for the life span of the animal. For this to occur, the worm must immuno-suppress the host. Nurse cell formation in skeletal muscle tissue is mediated by the hypoxic environment surrounding the new vessel formation. The hypoxic environment stimulates cells in the surrounding tissue to up-regulate and secrete angiogenic cytokines. These cytokines allow for the newborn *T. spinalis* larva to enter and form the nurse cell. Previous studies have shown that cytokines can stimulate proliferation of synthesis of collagen type 1 in activated myofibroblast like cells.



Nurse cell

Symptoms:

- The first symptoms may appear between **12 hours and two days** after ingestion of infected meat. The migration of worms in the intestinal epithelium can cause **traumatic damage** to the host tissue and the waste products they excrete can provoke an immunological reaction. The resulting inflammation can cause symptoms such as **nausea, vomiting, sweating and diarrhea**.
- **Five to seven days** after the appearance of symptoms **facial edema** and **fever** may occur.
- After **10 days** intense **muscular pain, difficulty breathing, weakening of pulse and blood pressure, heart damage and various nervous disorders** may occur, eventually leading to **death due to heart failure, respiratory complications or kidney malfunction**.

Diagnosis:

- **Muscle biopsy** is used for trichinosis detection.

- **Serological tests** and **microscopy** can be used to confirm a diagnosis of trichinosis. Serological tests include a blood test for **eosinophilia**, increased levels of **creatin phosphokinase**, and **antibodies** against newborn larvae.
- Immunoassays such as **ELISA** can also be used.

Treatment:

Typically patients are treated with either **Mebendazole** or **Albendazole** but efficiency of such products is uncertain. Symptoms can be relieved by use of **analgesics** and **corticosteroids**.



Capillaria spp. – Tiny Worms

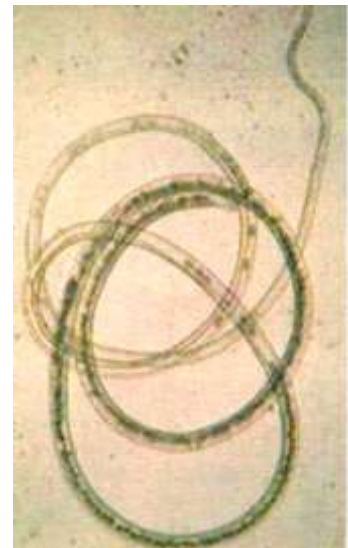
- ♣ **Capillaria spp.** are nematodes, or roundworms. There are many different species infecting a wide range of vertebrate hosts—a few occasionally infect human hosts causing serious parasitic disease. The best known of these are **C. hepatica** and **C. philippinensis**.
- ♣ **Capillariasis** is a disease caused by nematodes in the *Capillaria* genus. The two principal forms of the disease are:
 - 1- **Hepatic capillariasis**, caused by *C.hepatica*.
 - 2- **Intestinal capillariasis**, caused by *C. philippinensis*.

Scientific classification;

Kingdom: Animalia
Phylum: Nematoda
Class: Adenophorea
Subclass: Enoplia
Order: Trichurida
Family: Trichinellidae
Genus: *Capillaria*

Capillaria hepatica

Capillaria hepatica is a parasitic nematode which causes **hepatic capillariasis** in rodents and numerous other mammal species, including man. The life cycle of *C. hepatica* may be completed in a single host species. However, the eggs, which are laid in the liver, must mature outside of the host body (in the environment) prior to infecting a new host. So the death of the host in which the adults reach sexual maturity, either by being eaten or dying and decomposing, is necessary for completion of the life cycle.



Life cycle:

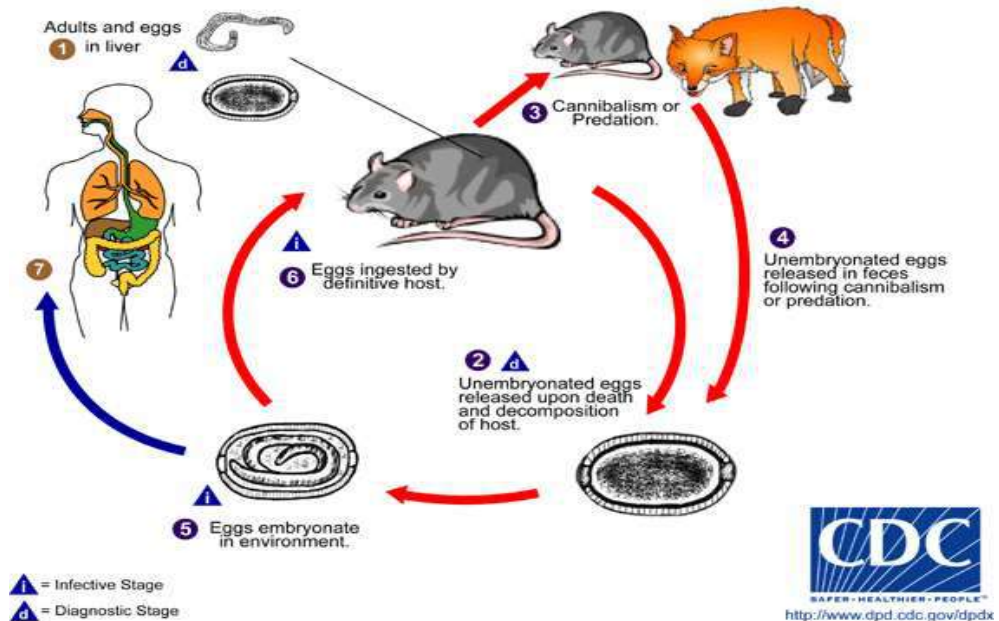
1. Hosts ingest *C. hepatica* eggs which hatch into first stage larvae (L1).

2. The L1 larvae bore through the intestinal wall and are carried to the liver by the hepatic portal vein.
3. Development from the L1 stage to sexually mature adults occurs in the liver within 18–21 days.
4. Eggs are laid in the liver parenchyma of the host throughout the adult worm's life span, which lasts for about 30–40 days. Up to 938,000 eggs have been reported from the liver of a single rodent host.

Note:

As the adult *C. hepatica* begin to die in the liver tissue, their decomposition accelerates the immune response of the host. This response leads to chronic inflammation and encapsulation of the dead worms in collagen fibers, and eventually to septal fibrosis (abnormal connective tissue growth) and cirrhosis of the liver. Meanwhile, the eggs in the liver exist in a state of arrested development; they are unable to develop into larvae until they spend some time outside of the host, in the environment. Escaping from the liver tissue may be accomplished either by the death and decomposition of the host's body, or by the consumption and digestion of the host by a predator or scavenger.

5. If the host is eaten, the eggs will pass into the environment in the feces of the predator.
6. In the environment, eggs require 4–5 weeks to develop, and may remain viable in a dormant state for several more months. Once these "environmentally-conditioned" eggs are eaten by a suitable host, the first stage larvae (L1) hatch in the intestine and continue the life cycle.



Life cycle of *Capillaria hepatica*

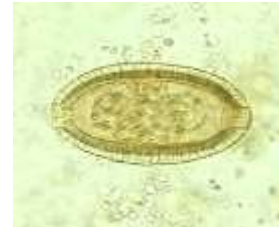Symptoms:

In human cases, symptoms of hepatic capillariasis include:

- Abdominal pain with fever and chills.
- Hepatitis (liver inflammation).
- Ascites (excess fluid in the peritoneal cavity).
- Hepatolithiasis (gallstones in the bile ducts).
- Hepatomegaly (enlarged liver).

Diagnosis:

Diagnosis is made by finding **eggs or adults** of *C. hepatica* in liver **biopsy** samples. The encapsulated eggs and adults may appear as white nodules which measure 2–3 mm in diameter on the surface and interior of the liver at autopsy.



Treatment:

Successful treatment of human cases with **thiabendazole or albendazole** (with or without **corticosteroids**) have been reported.



Dioctophyme renale

Dioctophyme renale is commonly referred to as “giant kidney worm” because it is the largest helminthes to parasitize humans and has the propensity to affect the kidneys. *D. renale* is distributed worldwide, but is less common in Africa and Oceania. It affects fish eating mammals, particularly mink and dogs. Human infestation is rare, but results in destruction of the kidneys. Upon diagnosis through tissue sampling, the only treatment is surgical excision.

Morphology:

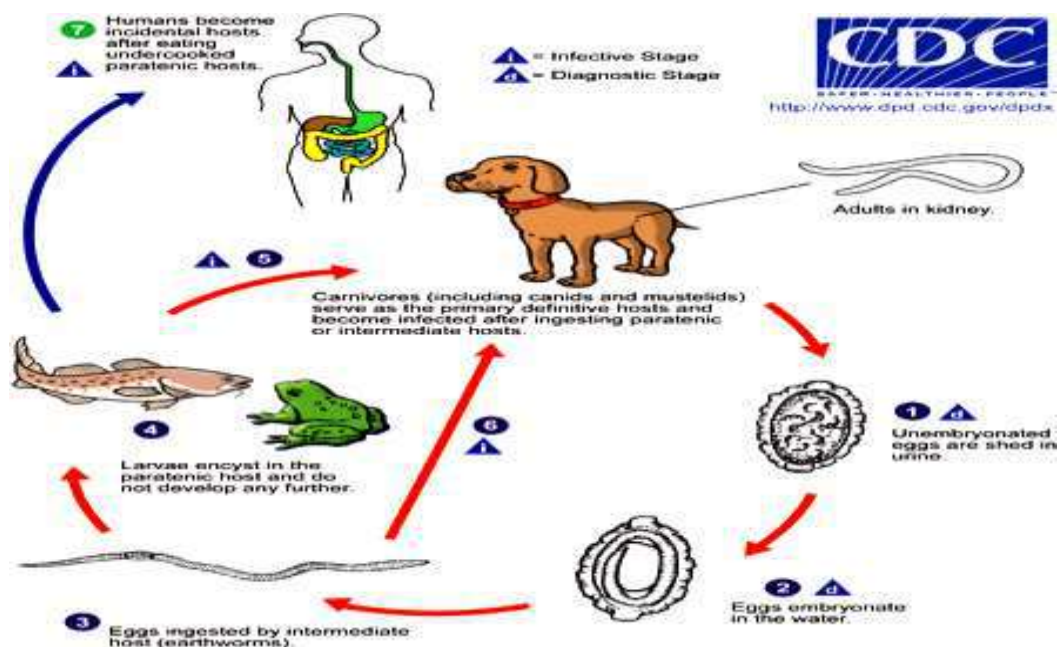
D. renale is the largest helminthes to parasitize humans. **Adult** male worms are 20–40 cm long and 5–6 mm wide; females can grow to 103 cm in length with a width of 10–12 mm. Both sexes appear bright red in color and taper at both the anterior and posterior ends. Male *D. renale* worms have a bursa, which is used to attach to facilitate mating.



Eggs are (60-80) x (39-47) micrometers, contain an embryo, and have characteristic sculpturing of the shell. They have an oval-shape and brownish-yellow hue. Eggs have a thick shell, and the surface appears to be pitted except at the poles.

Life cycle:

1. *Dioctophyma renale* eggs are laid in the kidneys of the definitive host (**mink, dog & human**) and passed in urine.
2. *D. renale* eggs need two weeks to three months in water, depending on temperature, to embryonate.
3. Infective eggs only hatch when ingested by an intermediate host of *D. renale*, generally an **annelid worm**. The first stage larvae (L1) penetrate the ventral blood vessel of the annelid host and develop through two molts into the **third stage larvae (L3)**.
4. When the intermediate host annelid is ingested by a fish, the third stage larvae L3 **encysts** in the abdominal muscle or wall of the digestive tube and the fish acts as a **paratenic host**.
5. L3 larvae of *D. renale* continue to **mature** until the paratenic host is eaten by a vertebrate definitive host, where they migrate from the intestine to the kidney and eventually reach **sexual maturity**



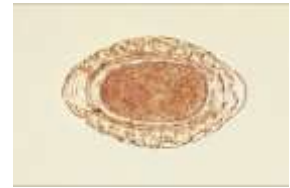Life cycle of *Dioctophyme renale*

Clinical presentation in humans

- Hematuria (blood in urine). Nephritis. Loin pain. Renal enlargement.
- Renal colic (intermittent pain in the kidney area), which may result from the rare migration of worms through ureters. Adult worms typically only infect one kidney. The kidney is **destroyed** because of **fibrosis**, the development of excess fibrous connective tissue. Renal function is typically limited because the non-infected kidney is usually capable of assuming the increased work. However, **parenchymal inflammation** can lead to **death** in extreme circumstances.

Diagnosis:

- The definitive diagnosis is through: identification of *D. renale* eggs in a patient's urine.
- **Radiological test** to search for **enlarged or calcified kidneys**.
- **Urinalysis** will likely show **hematuria**.
- **Blood tests** may reveal **eosinophilia**.

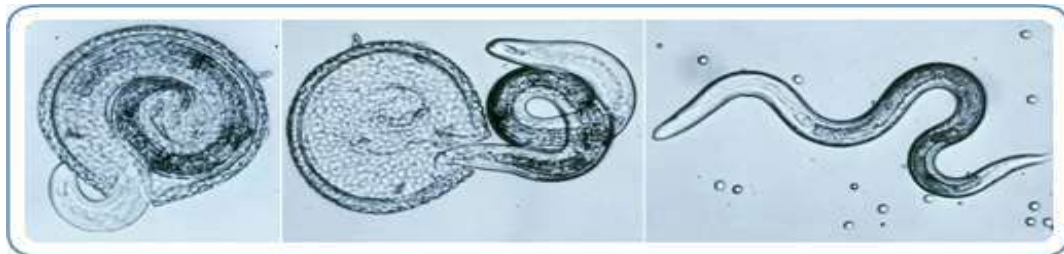


Treatment:

For *D. renale* infection in humans the only means of known means is **surgical excision of either adult worms or the infected kidney**. Nephrectomy is generally considered extreme for human cases. The use of **anti-helminth drugs** has not yet been evaluated as the proper course of action to treat this infection.



Toxocariasis (also known as Roundworm)



Toxocariasis is the parasitic disease caused by the larvae of two species of *Toxocara* roundworms: *Toxocara canis* from dogs and, less commonly, *Toxocara cati* from cats.

The life cycles of *T. canis* and *T. cati* are very complex and well-suited to exploiting the resources of their host animals. It is no wonder that over 90% of puppies and a significant number of kittens are infected.

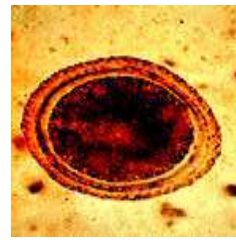
When an infected dog or cat defecates, microscopic eggs of *Toxocara* are present in the feces. These eggs are not infective immediately. They require a period of 3 to 4 weeks at environmental temperatures to develop into **infective larvae (L2)**. By this time there is no evidence of the fecal material, but the larva-containing eggs are in the soil. The eggs can remain infective for years, even though harsh environmental conditions. They are nearly impossible to kill with household disinfectants.

Dogs and puppies swallow the infective eggs along with grass or dirt, or contaminated toys. Rodents that contain developing larvae are another source of infection to dogs and cats that prey on them. Once an egg enters the intestinal tract of the dog or cat, the larva hatches out, then burrows out of the intestine and migrates through the animal's body. In very young puppies and kittens, it travels to the lungs, then the trachea, where it is coughed up and swallowed. Back in the intestines, the now-mature worm completes its life cycle by mating and laying eggs, which will be shed in the puppy's or kitten's stools. This entire cycle takes about 3 to 4 weeks.

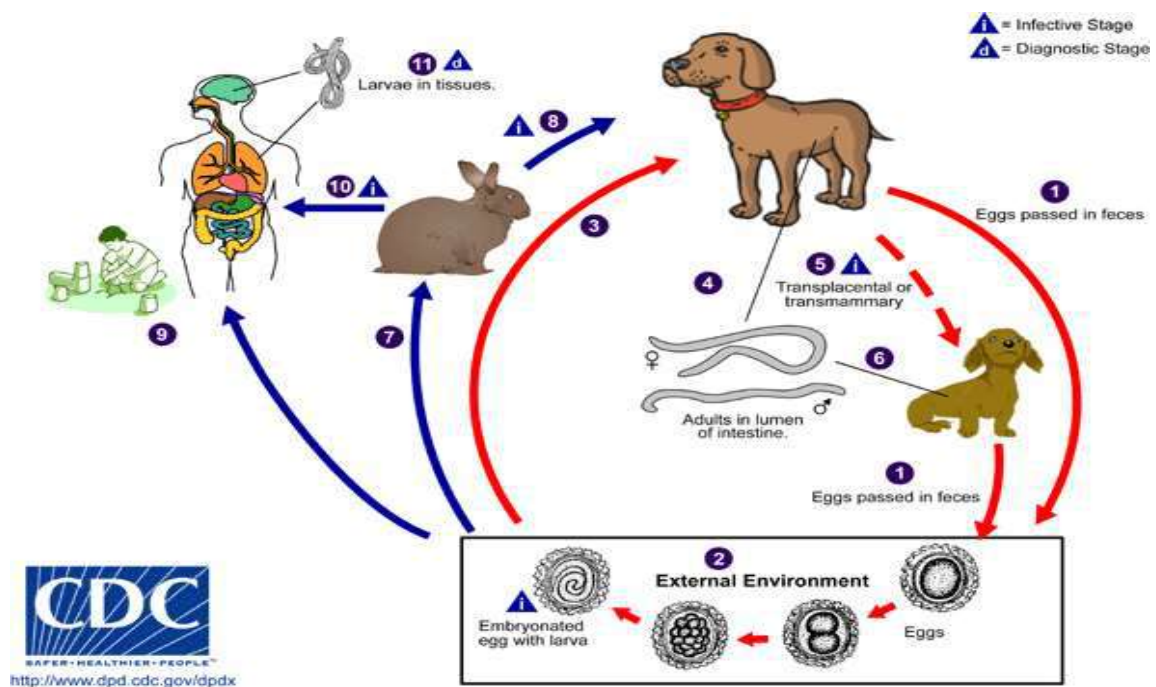
If the dog or cat is over 5 weeks old, the larva does not go to the lungs, instead entering the bloodstream where it travels until it reaches other tissues, especially the liver. There it encloses itself within a cyst and becomes dormant until reactivated by stress, illness or suppression of the animal's immune system, during the last few weeks of pregnancy in dogs, the encysted larvae are stimulated to head to the uterus, through the placenta, and into the lungs of the developing puppies. In cats and dogs, larvae end up in the mammary glands and pass into the newborns as they nurse. Thus many puppies are born infected, and kittens can become infected at a very early age, even though the mother's stools tested negative for worm eggs before her pregnancy.



Posterior end of *Toxocara* showing cervical alae



Toxocara ovum



Visceral larva migrans

Visceral larva migrans is a condition in humans caused by the migratory larvae of certain nematodes, humans being a terminal host. Nematodes causing such zoonotic infections are *Toxocara canis*, and *Toxocara cati*. These nematodes can infect but not mature in humans and after migrating through the intestinal wall, travel with the blood stream to various organs where they cause

inflammation and damage. Affected organs can include the liver, heart (causing myocarditis) and the CNS (causing dysfunction, seizures, and coma). A special variant is Ocular larva migrans where usually *T. canis* larvae travel to the eye. Young children may also become infected by eating dirt or sticking a dirty hand or toy into their mouths. This can result in Ocular or Visceral Larva Migrans, in which the worm larvae migrate into the eyes, causing vision loss, or throughout the body, causing generalized disease.

Symptoms

Mild infections may not cause symptoms.

More serious infections may cause the following symptoms:

- Abdominal pain. Cough, Fever , Irritability, Itchy skin (hives), Shortness of breath, Wheezing

If the eyes are infected (called ocular larva migrans), loss of vision and crossed eyes (strabismus) may occur.

Possible Complications

- Blindness
- Decreased visual acuity (worsened eyesight)
- Encephalitis (infection of the brain)
- Heart arrhythmias
- Respiratory distress

Treatment

This infection usually goes away on its own and may not require treatment. However, some people may need anti-parasitic drugs such as **albendazole**.

